Annals of Nuclear Medicine Vol. 3, No. 3, 149–152, 1989

Gallium-67 SPECT image in gastric lymphoma

Hitoya OHTA,*,** Keigo ENDO,** Toru FUJITA,** Hideki ADACHI,**
Junji KONISHI** and Hajime KOTOURA*

*Department of Radiology, Wakayama Red Cross Hospital
**Department of Nuclear Medicine, Kyoto University Hospital

Gastric non-Hodgkin lymphoma was unexpectedly detected by gallium-67 scanning in initial staging of the lesions. Single photon emission computed tomography was very useful in determining the accumulation site and indicating further appropriate examinations.

Key words: Malignant lymphoma, Stomach, Gallium-67, SPECT

INTRODUCTION

MALIGNANT LYMPHOMA, particularly non-Hodgkin lymphoma (NHL), occasionally originates in the stomach as a primary site or as a tumor involvement of generalized lymphoma.[1] We presented a case of malignant lymphoma whose gastric lesion was clearly visualized by gallium-67 citrate (Ga-67) using single photon emission computed tomography (SPECT) and was suspected to be a gastric NHL.

CASE REPORT

A 64-year-old man noticed a right cervical tumor of 1 cm in diameter. The tumor slowly increased in size and was accompanied with local fever and pain. Biopsy revealed NHL (diffuse medium-sized cell type). There was no other lymph node enlargement palpable. Ga-67 scanning was employed for the initial staging workup. The scanning was performed 72 hr after the i.v. injection of 3 mCi (111 MBq) Ga-67. SPECT (Maxi 400T, GE) was performed with 64 different views over 360 degrees and 30 seconds for every 5.6 degrees of rotation. Uniform attenuation correction was made. A strong accumulation in the left upper quadrant (LUQ) was found unexpectedly (Fig. 1). SPECT images showed that Ga-67 accumulation was ventral and not dorsal (Fig. 2 transaxial image, 3 coronal image). CT subsequently performed showed a diffusely thickened gastric wall (Fig. 4). SPECT and CT images suggested Ga-67 accumulation was in the stomach. Endoscopic examination demonstrated tumors similar to Borrmann 1 type carcinoma on the great curvature of the fornix, and histology revealed NHL (Fig. 5). The patient received nine courses of chemotherapy consisting of vincristine, cyclophosphamide and adriamycin and 40 Gy radiation therapy to the stomach. After therapy, Ga-67 scanning showed no abnormal accumulation (Fig. 6) and endoscopic examination revealed only gastritis (Fig. 7).

DISCUSSION

The usefulness of Ga-67 scanning in patients with NHL, even with gastric NHL, in evaluating the disease has been reported.[2,3] However abdominal lesions are less easily detected than those in other sites, because the activity may be superimposed on that of the liver, intestines, and spleen.[2,4] In this case, the correct interpretation of the Ga-67 accumulation site might be rather difficult with only planar images. SPECT clearly demonstrated that the accumulation was located in the stomach not in the spleen or colon. A Ga-67 accumulation in the stomach is not specific for NHL. It is also recognized in adenocarcinoma,[5] gastritis[6] and even in a normal stomach.[7] However in patients with NHL, when a Ga-67 accumulation is found in the LUQ, SPECT should be positively employed to determine the

Received May 29, 1989; revision accepted August 11, 1989.

For reprints contact: Hitoya Ohta, Department of Radiology, Wakayama Red Cross Hospital, 4–1, Komatsubaradori, Wakayama 640, JAPAN

Fig. 1 Ga-67 images show strong accumulation in the left upper quadrant.

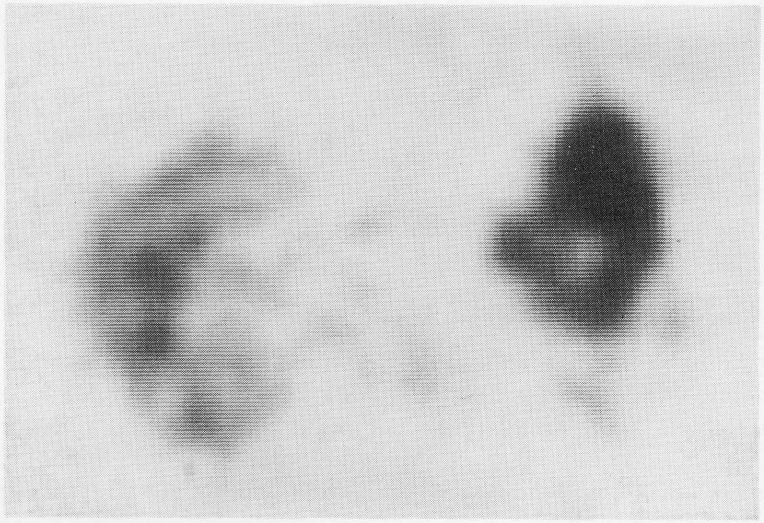

Fig. 2 SPECT transaxial image suggests Ga-67 accumulates in the stomach.

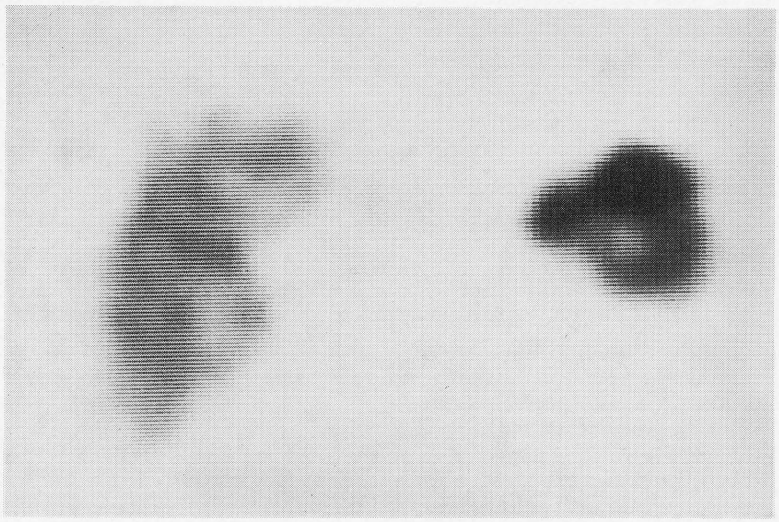

Fig. 3 SPECT coronal image also suggests Ga-67 accumulates in the stomach.

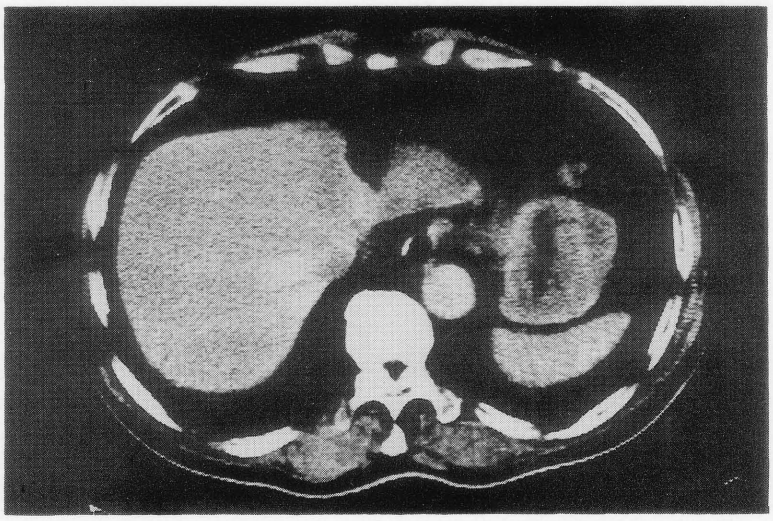

Fig. 4 CT shows a diffuse thickening of the gastric wall.

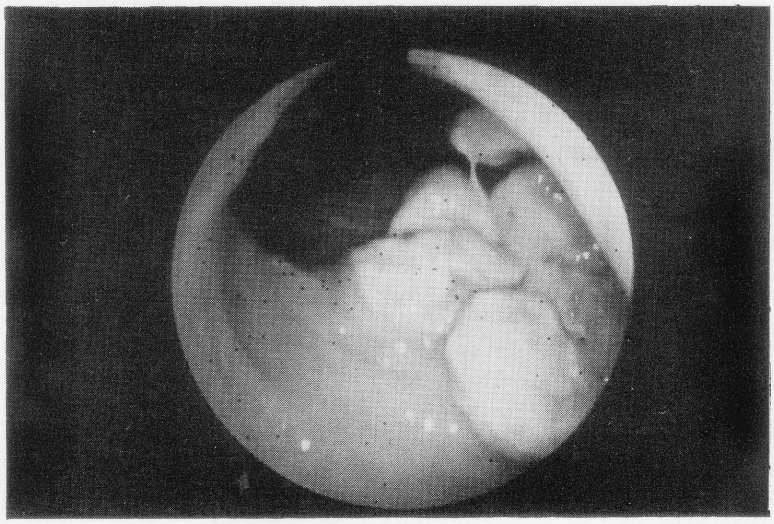

Fig. 5 Endoscopic picture shows multiple tumors which reveal non-Hodgkin lymphoma on the great curvature of the fornix.

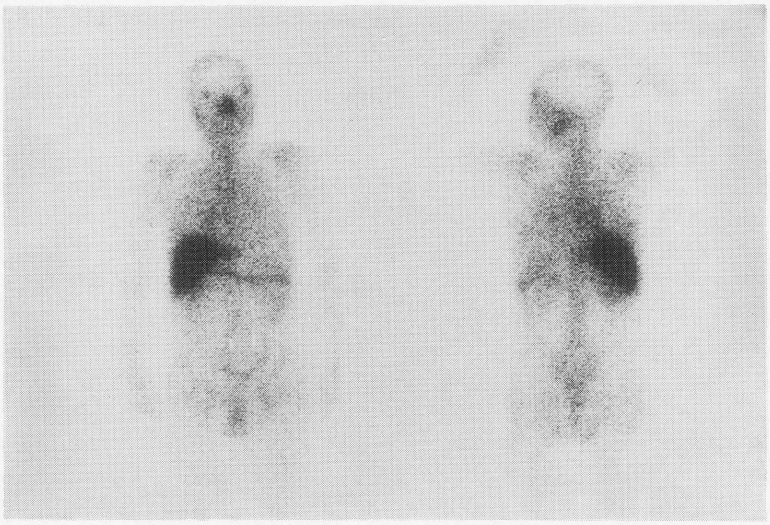

Fig. 6 After therapy, Ga-67 images show no abnormal accumulation.

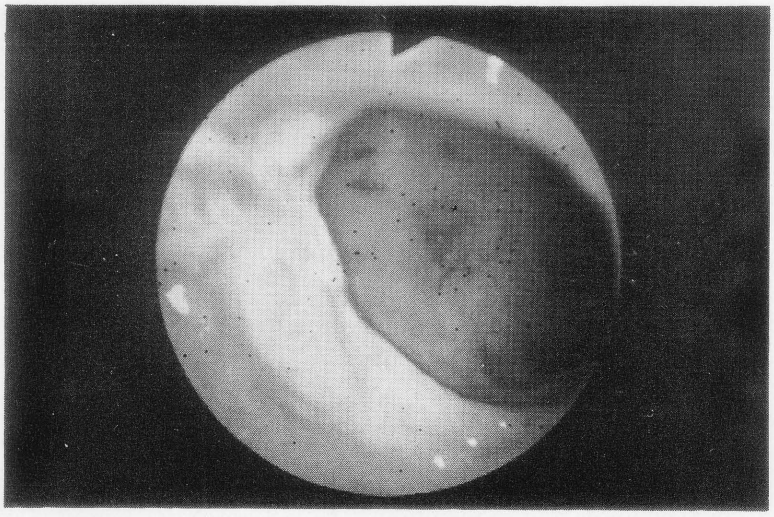

Fig. 7 Endoscopic picture shows the disappearance of the tumors.

nature of the lesions and to indicate further appropriate examinations.

ACKNOWLEDGMENTS

The authors thank Mr. Kunihiko Tsuno, Mr. Tetsuo Murakami, Mr. Nobufusa Yoshimura and Mr. Fumio Umeda for their valuable assistance.

REFERENCES

1. Nelson RS: Malignant tumors of the stomach other than carcinoma. In *Gastroenterology 3rd ed, Volume 1*, Bocus HL (ed), Philadelphia, Saunders, pp. 998–1007, 1974
2. Ichiya Y, Oshiumi Y, Kamoi I, et al: ^{67}Ga scanning and upper gastrointestinal series for gastric lymphomas. *Radiology* 142: 187–192, 1982
3. Gianfelice D, Rosenthall L, Falutz J: Gallium-67 detection of occult gastric lymphoma in AIDS. *AJR* **49**: 305–306, 1987
4. Larson SM, Milder MS, Johnston GS: Interpretation of the ^{67}Ga photoscan. *J Nucl Med* 14: 208–214, 1973
5. Douds HN, Berens SV, Long RF, et al: ^{67}Ga citrate scanning in gastrointestinal malignancies. *Clin Nucl Med* 3: 179–183, 1978
6. Eikman EA, Tenorio LE, Frank BA, et al: Gallium-67 accumulation in the stomach in patients with postoperative gastritis. *J Nucl Med* 21: 706–707, 1980
7. MacMahon H, Vyborny C, Sephardari S, et al: Gallium accumulation in the stomach a frequent incidental finding. *Clin Nucl Med* 10: 719–723, 1985