

## The ability of $^{67}\text{Ga}$ scintigraphy to detect the lesions of *Echinococcus multilocularis* infection: Preliminary results

T. INCEBOZ,\* A. MAVI,\*\* G. ÇAPA KAYA,\*\* M. KORKMAZ,\*\*\* Y. GOKTAY,\*\*\*\*  
O. YILMAZ,\*\*\*\*\* A. UNER\*\*\* and H. DURAK\*\*

\*Department of Parasitology, School of Medicine, Dokuz Eylül University, Izmir, Turkey

\*\*Department of Nuclear Medicine, School of Medicine, Dokuz Eylül University, Izmir, Turkey

\*\*\*Department of Parasitology, School of Medicine, Ege University, Izmir, Turkey

\*\*\*\*Department of Radiology, School of Medicine, Dokuz Eylül University, Izmir, Turkey

\*\*\*\*\*Experimental Research Center, School of Medicine, Dokuz Eylül University, Izmir, Turkey

**Aim:** To assess the ability of  $^{67}\text{Ga}$  scintigraphy to detect the lesions of *Echinococcus multilocularis* (EM) infection. **Materials and Methods:** An animal model of EM infection was developed. The infected tissues taken from stock infection were placed into the abdominal cavity of uninfected animals operatively. The success of implantation was controlled 20–25 days after implantation. Five infected and 2 healthy animals were studied. All of the animals were examined by ultrasound before the scintigraphic evaluation. After the injection of 7.4 MBq (200  $\mu\text{Ci}$ )  $^{67}\text{Ga}$  citrate intravenously, static images from the whole anterior thorax and abdomen were obtained at 24, 48 and 72 hours. Visual and semiquantitative analyses were performed. In semiquantitative analysis, an irregular region of interest was drawn over the thorax as the background, excluding the heart and a second region of interest was drawn over the abdomen, excluding the liver and spleen. Abdomen/background ratios were calculated using the mean counts. **Results:** In the visual evaluation, it was noticed that there was considerably increased  $^{67}\text{Ga}$  uptake in the abdomens of the infected animals. In infected animals, mean abdomen/background ratios at 48 and 72 hours ( $3.76 \pm 1.04$ ,  $4.13 \pm 0.72$ , respectively) were increased compared with mean abdomen/background ratios at 24 hours ( $2.94 \pm 0.77$ ). These increases in abdomen/background ratios were statistically significant at 72 hours ( $p = 0.04$ ). Between the infected animals and control group, mean abdomen/background ratios were compared, and statistically significant differences were found in the images obtained at 48 and 72 hours. **Conclusion:** Imaging at 72 hours seems to be more suitable imaging time for the diagnosis of alveolar echinococcosis.  $^{67}\text{Ga}$  scintigraphy may successfully demonstrate the lesions of EM infection localized intraperitoneally. The method of  $^{67}\text{Ga}$  scintigraphy is useful because it is simple, non-invasive and relatively safe.

**Key words:** gallium scintigraphy, infection, *Echinococcus multilocularis*

### INTRODUCTION

THE LARVAL STAGE of the fox tapeworm *Echinococcus multilocularis* (EM), a parasite prevalent in the Northern

Received November 14, 2005, revision accepted March 28, 2006.

For reprint contact: Gamze Çapa Kaya, M.D., Dokuz Eylül University, School of Medicine, Department of Nuclear Medicine, 35340, Inciralti, Izmir, TURKEY.

E-mail: gamze.capa@deu.edu.tr

Hemisphere, is the causative agent of human alveolar echinococcosis, which is considered to be the most lethal helminthic infection in humans.<sup>1</sup> Traditional radiological imaging methods can be used to diagnose the infection and inflammatory processes by detecting the results of anatomical changes, but in the early phase of the disease, anatomical changes may be insufficient for the diagnosis. In addition, it can be difficult to differentiate active disease from successfully treated processes or postoperative changes. Furthermore, radiological methods usually image a body region, not the whole body.<sup>2</sup>

Scintigraphic methods have been used for some parasitic diseases such as *Schistosoma mansoni* colitis,<sup>3</sup> *Fasciola hepatica*,<sup>4</sup> cyst infection,<sup>5</sup> unusual localization of *Echinococcus granulosus*.<sup>6,7</sup> Gallium-67-citrate localizes at the site of inflammation as a result of binding to bacterial siderophores, macrophage ferritin, and polymorphonuclear lactoferrin with increased blood flow and vascular permeability of the capillaries.<sup>2,8</sup> Although <sup>67</sup>Ga was the first evaluated agent in tumor-scanning, its value for detection of inflammations and infections was also recognized.<sup>9</sup> After intravenous administration, over 90% of <sup>67</sup>Ga binds to iron-binding serum proteins such as, transferrin, ferritin and lactoferrin which results in the localization of inflammation.<sup>2,9</sup>

There have been some difficulties in the diagnosis of early phase alveolar echinococcosis and differentiating active from inactive disease. In a recent study,<sup>10</sup> pericyclic metabolic activity in alveolar echinococcosis was successfully shown by positron emission tomography (PET). [<sup>18</sup>F]fluorodeoxyglucose (FDG) was localized in inflammation, so FDG PET may differentiate active infected tissue from dead parasitic tissue. <sup>67</sup>Ga, similarly to FDG, may localize in inflammation and demonstrate active infected tissue.

The aim of this study was to assess the ability to detect the lesions of EM infection using <sup>67</sup>Ga scintigraphy.

## MATERIALS AND METHODS

### Experimental Design

EM metacystodes were taken from stock infection and grafted into a gerbil intraperitoneally. The gerbil was examined by palpation of the masses, then ultrasonography and scintigraphy 20–25 days after the implantation, after which the gerbil was sacrificed. The EM vesicles were sampled, examined histopathologically, and processed to prepare implantation material for the next experiment.<sup>11</sup>

Five healthy female, 8–12-week-old, *Meriones unguiculatus* (species approximately 60–70 g) were chosen for the study, as they are known to be susceptible to EM infection. The exclusion criterion from the research was determined to be the presence of an infection or systemic reaction to the implanted vesicles. Two healthy, 8–12-week-old, *Meriones unguiculatus* (approximately 60–70 g weight) were also included as a control group.

For protecting the personnel from alveolar echinococcosis infection, sterile gloves were used with protective masks for the face and eyes to avoid any danger in case of splashing in the sterile conditions of the security chamber.

All the experiments in this study were carried out in compliance with the relevant national laws relating to the conduct of animal experimentation. Additionally, the study was approved by the local Ethics Committee of the Experimental Studies at Dokuz Eylül University, School of Medicine.

### Ultrasonography

All of the animals were examined by ultrasound before the scintigraphic studies. Abdominal ultrasonographic examinations were performed for the infected animals to demonstrate intraabdominal lesions on day 20–25 after implantation with a linear probe (5–12 MHz, ATL-HDI 5000, Bothell, Washington, USA) with the superficial imaging algorithm.

### Scintigraphy

Scintigraphic examinations were performed just after the ultrasonographic examinations (20–25 days after the implantation). After the injection of 7.4 MBq (200  $\mu$ Ci) <sup>67</sup>Ga citrate intravenously via the femoral vein, static images from whole anterior thorax and abdomen were obtained at 24, 48 and 72 hours post injection (256  $\times$  256 matrices, 2 zoom, 30 min/per each) by using a medium energy collimator with the XR/T gamma camera (General Electric, St. Albans, UK).

Visual and semiquantitative evaluations were performed. Three independent nuclear medicine specialists evaluated the scintigraphies visually, and semiquantitative analysis of the <sup>67</sup>Ga images of all the animals was performed. In visual evaluation, first normal <sup>67</sup>Ga uptake pattern was demonstrated in healthy Mongolian gerbils (*Meriones unguiculatus*). After that <sup>67</sup>Ga uptake in infected animals was evaluated visually, and the findings were correlated with the ultrasonographic examinations.

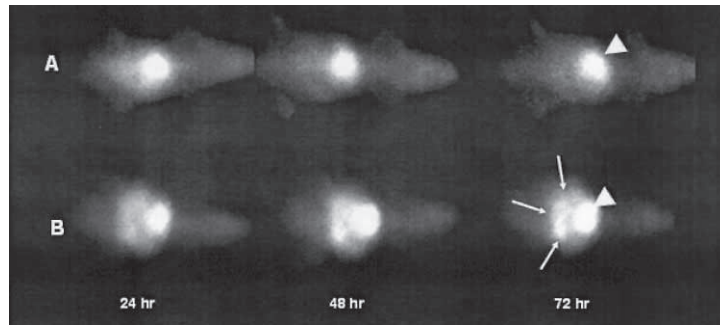
In semiquantitative analysis, because the lesions of EM infection were localized intraperitoneally, a region of interest was drawn over the abdomen, excluding the liver and spleen and a second region of interest was drawn over the thorax as the background, excluding the heart. By this method, abdomen/background ratios were calculated using mean counts at 24, 48 and 72 hours images to demonstrate <sup>67</sup>Ga uptake in EM lesions localized intraperitoneally.

### Histopathology

After the imaging at the Nuclear Medicine department, the radioactive animals were anesthetized with ether, and sacrificed by cervical dislocation. An abdominal incision of 2–3 cm was performed in the midline, and the animals were examined to confirm the parasitic infection macroscopically and microscopically. The preparations which were prepared from the infected material were examined histopathologically under a light microscope, and vesicles of EM and protoscolex formations were identified. In this way, the presence of infection is justified by the golden standard method. Later, an equal volume of physiological saline is added to the isolated material to prepare the inoculation material.

### Statistical Analyses

All results were expressed as mean  $\pm$  SD. Data sets obtained from infected animals and control group at the



**Fig. 1** A)  $^{67}\text{Ga}$  uptake of a healthy (uninfected) *Meriones unguiculatus* at 24th, 48th and 72nd-hours post injection. Liver uptake is seen (arrowhead). B)  $^{67}\text{Ga}$  uptake of a *Meriones unguiculatus* infected with EM at 24th, 48th and 72nd-hours post injection. Liver (arrowhead) and pathologic  $^{67}\text{Ga}$  uptake (arrows) are shown. Marked prominent abdominal uptake is seen at 24, 48 and 72 hours.

**Table 1** Abdomen/background ratios of  $^{67}\text{Ga}$  for the infected and control groups at 24, 48 and 72 hours

Imaging time (hours)	Abdomen/background ratios		p-values
	Infected group	Control group	
24	$2.94 \pm 0.77$	$1.62 \pm 0.09$	Not significant
48	$3.76 \pm 1.04$	$1.77 \pm 0.24$	0.02
72	$4.13 \pm 0.72$	$1.77 \pm 0.24$	0.01

$p \leq 0.05$  was accepted as statistically significant.

24, 48 and 72 hours were compared by analysis of variance (ANOVA) using SPSS 11.0 for Windows to investigate whether there was any differences in abdomen/background ratios between infected animals and control group. For infected animals, the differences in abdomen/background ratios between 24, 48 and 72 hours were studied to show the most suitable imaging time for EM infection. A p-value less than 0.05 was considered statistically significant.

## RESULTS

The diagnosis of EM infection was demonstrated histopathologically in all animals.

The sonographic examinations of the infected animals revealed lobulated, heterogeneous cystic intraabdominal masses. There were echogenic solid areas with hypoechoic and anechoic cystic areas within the lesions. In most of the infected animals, the lesions occupied almost the entire intraabdominal cavity (the average size of the lesions was  $2.2 \pm 0.6 \times 1.6 \pm 0.5 \times 2.8 \pm 0.5$  cm). There was no sign of solid abdominal organ infiltration or invasion on sonographic examinations of the infected animals, and the liver appeared normal in all animals. Sonographic examinations of the animals in the control group were normal.

In visual evaluation, it was noticed that there was considerably increased and irregular  $^{67}\text{Ga}$  uptake in the intraperitoneal lesions of the infected animals (Fig. 1).

To investigate the optimal imaging time, intensity of

$^{67}\text{Ga}$  uptake at 24, 48 and 72 hours was compared for infected animals. Mean abdomen/background ratios at 48 and 72 hours ( $3.76 \pm 1.04$ ,  $4.13 \pm 0.72$ , respectively) were increased compared with mean abdomen/background ratios at 24 hours ( $2.94 \pm 0.77$ ). These increases in abdomen/background ratios were statistically significant at 72 hours ( $p = 0.04$ ), but statistical significance was not found for 48 hours.

For infected animals and control group, mean abdomen/background ratios at 24, 48 and 72 hours were given in Table 1. When comparing mean abdomen/background ratios between the infected animals and control group, statistically significant differences were found in the images obtained at 48 and 72 hours.

## DISCUSSION

There have been some reports demonstrating that  $^{67}\text{Ga}$  scintigraphy may be useful in some parasitary disease. It has been previously reported that *Schistosoma mansoni* colitis is diagnosed with persistent colonic activity on  $^{67}\text{Ga}$  scintigraphy.<sup>3</sup> In addition, some scintigraphic methods have been used in the diagnosis of different parasite diseases such as *Fasciola hepatica*,<sup>13</sup> and unusual localization of *Echinococcus granulosus*.<sup>6,7</sup>

EM is the causative parasite of alveolar echinococcosis, and it is different from *Echinococcus granulosus*, the causative parasite of hydatid disease. In contrast to *Echinococcus granulosus*, the larvae of EM grow indefinitely; they produce liver necrosis and induce a major granulomatous reaction. The disease caused by EM may involve not only the liver but also other organs such as the lungs, brain, and spleen.<sup>13</sup> In the diagnosis of EM infection, serological and radiological methods are used.<sup>12,14</sup> However, serologically there may be cross reaction between EM and *Echinococcus granulosus*.<sup>14</sup> Imaging findings in hydatid disease caused by *Echinococcus granulosus* are well documented in the literature, but the radiological features of alveolar echinococcosis are nonspecific.<sup>12</sup>

Additionally, radiologically the disease may be misdiagnosed as carcinoma of the liver since it yields a massy appearance.<sup>12</sup> Difficulties also exist in differentiating active from inactive disease.

Further techniques such as scintigraphy may be useful for evaluating the extent of the diagnosis of EM infection. <sup>67</sup>Ga is taken up particularly in the liver, less in the spleen, bone marrow, skeleton, nasal mucosa, lachrymal and salivary glands, external genitalia and lactating breasts.<sup>15</sup> Most of these organs may be involved in alveolar echinococcosis. Though increased <sup>67</sup>Ga uptake may not differentiate cancer from inflammation, <sup>67</sup>Ga scintigraphy may be beneficial in the diagnosis of metabolically active alveolar echinococcosis in the liver.

Reuter et al. demonstrated that FDG PET may have a role in the response to therapy in patients with EM infections.<sup>10</sup> We demonstrated intraperitoneally localized EM infection using <sup>67</sup>Ga scintigraphy in our study. Though liver localization of EM may be a limitation for <sup>67</sup>Ga scintigraphy, the majority of patients with EM will be diagnosed with large masses even in the earlier period of disease because of the lack of overt clinical symptoms. The masses in liver were rather large (minimum mass in diameter with 2.5 × 1.8 cm, maximum: 8 × 5 cm) in a recent PET study.<sup>10</sup> The physiological <sup>67</sup>Ga uptake in liver may interfere with the evaluation of liver lesions but in EM infection liver lesions were very large masses, so <sup>67</sup>Ga scintigraphy may localize such large lesions due to their metabolic activity, even when the lesions are localized in liver. According to our knowledge, there is no study about alveolar echinococcosis (and/or also hydatid disease) and <sup>67</sup>Ga scintigraphy in the literature.

Furthermore the statistically significant differences found between the infected animals and control group in the images obtained at 48 and 72 hours reveal objective data of the disease. In infected animal group, imaging at 72 hours is seems to be the most suitable imaging time when <sup>67</sup>Ga scintigraphy is used to investigate alveolar echinococcosis.

In this experimental study, the lesions of EM infection were successfully demonstrated by <sup>67</sup>Ga scintigraphy. The irregular increased <sup>67</sup>Ga uptake was consistent with the sonographic evaluation. Both the limited number of animals and lack of the clinical experience in patients infected with EM are the limitations of our study.

In conclusion, we have documented that <sup>67</sup>Ga scintigraphy could successfully demonstrate the lesions of EM, the causative parasite of alveolar echinococcosis disease. The method of scintigraphy with <sup>67</sup>Ga is useful because it is simple, noninvasive and relatively safe. There is a need for studies both to investigate the diagnostic value of <sup>67</sup>Ga scintigraphy in EM infection localized in liver and assess the therapy response of EM infection. When PET study is

not available, <sup>67</sup>Ga scintigraphy may be an alternative imaging modality to FDG PET in the diagnosis and follow up of EM infection.

## REFERENCES

1. Rausch RL. Life cycle patterns and geographic distribution of *Echinococcus* species. In *Echinococcus and Hydatid disease*, Thompson RCA, Lymbery AJ (eds.), Wallingford, CAB International, 1995: 89–134.
2. Thrall JH, Ziessman HA. Infection and Inflammation. In *Nuclear Medicine (The Requisite)*, Thrall JH, Ziessman HA (eds.), St. Louis; Mosby, 2001: 69–192.
3. Chandramouly B, Rabin G, Schiano F. *Schistosoma mansoni* colitis in AIDS. Ga-67 scintigraphic findings. *Clin Nucl Med* 1995; 20: 72.
4. Rivera JV, Bermudez RH. Radionuclide imaging of the liver in human fascioliasis. *Clin Nucl Med* 1984; 9: 450–453.
5. Al-Nahas AM, Steel JR. Demonstration of infection of one cyst in a polycystic liver with Ga-67 citrate SPECT. *Clin Nucl Med* 2000; 25: 224–226.
6. Yildirim M, Varoglu E, Gursan N, Yildirim U, Erdogmus B, Dalga S. Unusual localization of hydatid cyst: bone scintigraphy, brain SPECT, and magnetic resonance imaging findings. *Clin Nucl Med* 2002; 27: 49–50.
7. Demirkol MO, Kurtoglu N, Keles C, Sismanoglu M, Turan F. Hydatid cyst of the interventricular septum: an unusual cause of a fixed myocardial perfusion defect. *Clin Nucl Med* 2001; 26: 716–717.
8. Wilson MA, La Pena R. Infection. In *Textbook of Nuclear Medicine*, Wilson MA (ed.), Philadelphia New York; Lippincott-Raven, 1997: 189–192.
9. Neumann RD, McAfee JG. Gallium-67 imaging in infection. In *Diagnostic Nuclear Medicine*, Sandler MP, Coleman RE, Patton JA (eds.), Philadelphia; Lippincott Williams & Wilkins, 1998: 1205–1217.
10. Reuter S, Schirrmeister H, Kratzer W, Dreweck C, Reske SN, Kern P. Pericystic metabolic activity in alveolar echinococcosis: assessment and follow-up by positron emission tomography. *Clin Infect Dis* 1999; 29: 1157–1163.
11. Persat F, Mojon M, Petavy AF. Lipids of *Echinococcus multilocularis* metacestodes. *Comp Biochem Physiol* 1988; 91: 133–136.
12. Reuter S, Seitz HM, Kern P, Junghans T. Extrahepatic alveolar echinococcosis without liver involvement: a rare manifestation. *Infection* 2000; 28: 187–192.
13. Liance M, Janin V, Bresson-Hadni S, Vuitton DA, Houin R, Piarroux R. Immunodiagnosis of *Echinococcus* infections: confirmatory testing and species differentiation by a new commercial Western Blot. *J Clin Microbiol* 2000; 383: 718–721.
14. Akin O, Isiklar I. Hepatic alveolar echinococcosis. *Acta Radiologica* 1999; 40: 326–328.
15. Vizda J, Urbanova E. *Atlas of Gallium Scintigraphy*. Prvnivydani, Praha; Petit Press sro, 2001.