

Cerebral blood flow abnormalities induced by transient hypothyroidism after thyroidectomy —Analysis by Tc-99m-HMPAO and SPM96—

Shigeki NAGAMACHI,* Seishi JINNOUCHI,* Ryuichi NISHII,***** Yasushi ISHIDA,** Seigo FUJITA,*
Shigemi FUTAMI,* Takao KODAMA,* Shozo TAMURA* and Keiichi KAWAI*****

*Department of Radiology, Miyazaki Medical College

**Department of Psychiatry, Miyazaki Medical College

***School of Health Science, Faculty of Medicine, Kanazawa University

****Division of Radiopharmaceutical Chemistry, Biomedical Imaging Research Center, Fukui University

The current study is an investigation of alterations in regional cerebral blood flow (rCBF) distribution in patients with transient hypothyroidism after thyroidectomy. In addition, the effects of thyroxine treatment on rCBF changes were studied. **Methods:** Noninvasive rCBF measurements using ^{99m}Tc-HMPAO SPECT were performed on 24 post-thyroidectomy patients who were in a hypothyroidic state. The measurements were conducted before ¹³¹I therapy and after thyroid hormone (thyroxine) replacement. We used adjusted rCBF images (normalization of global CBF for each subject to 50 ml/100 g/min with proportional scaling) to compare these data with age-matched normal control groups (n = 15) using SPM96. We also compared the absolute rCBF value of hypothyroidic patients with those of normal control groups. In addition, the association between rCBF alteration and the severity of depression was also analyzed. Finally, the effect of thyroid hormone replacement on rCBF was investigated individually using the Jack-knife test, in which patient data were compared with those from healthy volunteers. According to the result of this test, all cases were categorized into three subgroups, namely, improved, unchanged group and normal. To prove the reversibility of rCBF alteration after thyroid hormone replacement, a group comparison test between the normal controls and the improved group was done before and after thyroid hormone replacement. Similarly a group comparison test between the unchanged group and normal controls was also performed. **Results:** In the hypothyroidic condition, there was a significant decrease in the posterior part of the bilateral parietal lobes and in part of the bilateral occipital lobes, including the cuneus. These decreased rCBF areas extended to the bilateral prefrontal cortices as deterioration became more profound. On individual analysis, 16 of 24 patients (66.7%) demonstrated rCBF reduction, while 8 patient did not show significant rCBF change (33.3%, the normal group). After thyroxine replacement, improvement of rCBF was noted in nine of 16 patients (56.3%, the improved group). In seven of 16 patients (43.7% the unchanged group), the significant low rCBF area remained unchanged. Compared with the normal controls, the improved group showed significantly decreased rCBF of the bilateral parietal lobe and the occipital lobe in the hypothyroidic condition. After thyroid hormone replacement, these abnormal rCBF areas disappeared. In contrast, in the unchanged group, the significant hypoperfusion area became localized but remained. **Conclusion:** ^{99m}Tc-HMPAO SPECT and SPM96 analysis demonstrated a significant rCBF decrease in the parietal lobe and part of the occipital lobe in patients with induced transient hypothyroidism after thyroidectomy. This phenomenon might contribute to understanding of the depressive state. Recovery of rCBF after thyroid hormone replacement was confirmed in some

Received May 27, 2003, revision accepted April 19, 2004.

For reprint contact: Shigeki Nagamachi, M.D., Department of Radiology, Miyazaki Medical College, Kihara 5200, Kiyotake,

Miyazaki 889–1692, JAPAN.

E-mail: snagama@post1.miyazaki-med.ac.jp

patients. However, rCBF improvement did not always occur in every patient during the follow up period. The reversibility of rCBF in transient hypothyroidism may be dependent on individual characteristics during a short-term period.

Key words: ^{99m}Tc -HMPAO, regional cerebral blood flow, transient hypothyroidism, SPM96 (statistical parametric mapping), thyroxin replacement therapy, post-thyroidectomy

INTRODUCTION

HYPOTHYROIDISM is associated with disturbances in mood and intellectual function.¹⁻³ Because of the close relationship between these psychiatric conditions and cerebral blood flow (rCBF), it is possible that thyroid hormone depletion could result in an alteration of rCBF. Previously, the rCBF of hypothyroidic patients with apparent clinical psychiatric symptoms was reported to be decreased.⁴⁻⁶ However, the rCBF changes related to induced transient hypothyroidism, such as pre- ^{131}I -therapy conditions, remain unclear.

Because ^{131}I therapy after total thyroidectomy is sometimes problematic due to psychiatric disturbances, the association between the symptom and the rCBF alteration should be elucidated. Recently, Constant et al. reported that diffuse rCBF reduction and decreased glucose metabolism could be observed by PET studies even in induced hypothyroidism.⁷

To confirm the previous report using more convenient SPECT equipment, we performed ^{99m}Tc -HMPAO SPECT to investigate the relationship between this psychiatric issue and rCBF changes in the short-term hypothyroidic state before ^{131}I therapy. The reversibility of possible rCBF alterations by thyroid hormone replacement after ^{131}I therapy was also investigated. We applied SPM96 (statistical parametric mapping) analysis to avoid subjectivity, such as intensive ROI placement to establish differences with normal tracer distribution on functional activity maps.^{8,9}

MATERIALS AND METHODS

Subjects

We studied 24 patients who had undergone total thyroidectomy due to thyroid cancer (6 men, 18 women; mean age: 55.4 years; range: 23–76 years). All patients were hospitalized for ^{131}I therapy. For 14 of the 24 patients, this was the first use of ^{131}I irradiation therapy after thyroidectomy. For six patients, it was the second time, and for four, it was the third time. The period between the baseline study and thyroidectomy was longer than 40 days at least (53.5 ± 12 days). All patients were free of thyroid hormone replacement therapy at least 3 weeks before the baseline study. Hypothyroidism was diagnosed by serum T4 (mean value: $2.0 \pm 2.9 \mu\text{g/dl}$), T3 (mean value: $0.33 \pm 0.28 \text{ ng/ml}$), and TSH (mean value:

$120.1 \pm 86.2 \mu\text{IU/ml}$). Patients with a history of known cerebro-vascular disease or psychiatric disease were excluded. All subjects underwent MRI examinations, and patients with organic lesions were excluded.

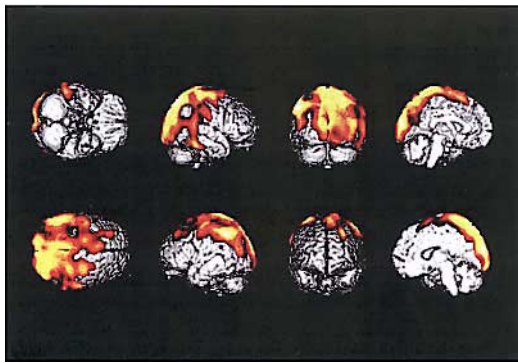
A self-assessment test for depression (SDS) was done to evaluate their psychiatric condition. Although each subject was free of apparent typical symptoms, such as apathy, their scores on the SDS test categorized them as suffering from mild (<39), moderate (40–49), or severe (<50) depression or neurosis. Fifteen control subjects (8 men, 7 women; mean age, 56.7 years; range: 32–76 years) were also studied. They were healthy volunteers who had no neurological or psychiatric disorders, including alcoholism, substance abuse, atypical headache, head trauma, or asymptomatic cerebral infarction detected by T2-weighted MRI. The portion of the study involving healthy volunteers was approved by the ethics committee of Miyazaki Medical College. All healthy volunteers and all patients gave informed consent. After the course of ^{131}I therapy, all subjects were restored to the euthyroidic condition by thyroxine replacement. The follow-up studies were performed in the euthyroidic state. The mean period between the baseline study and the follow-up study was 71.6 ± 37.4 days.

Brain SPECT procedure

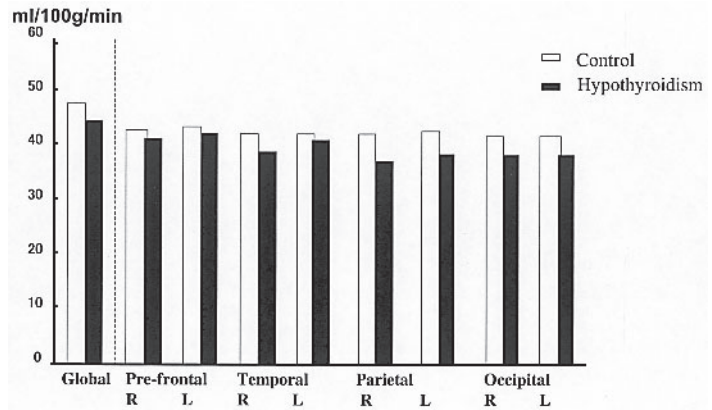
Before undergoing SPECT, all subjects received an intravenous line while lying down with their eyes closed. Each subject received a 600 MBq intravenous injection of ^{99m}Tc -HMPAO (PAO). A dynamic study was done for calculating absolute rCBF value using graphic analysis.¹⁰ Ten minutes after this injection, the brain SPECT was performed using a triple-head gamma camera (Prism 3000; Marconi) equipped with a high-resolution fanbeam collimator. For each camera, projection data were obtained in a 128×128 format for 24 angles of 120° at 50s per angle. A Shepp and Logan Hanning filter was used for SPECT image reconstruction at 0.7 cycle per centimeter. Attenuation correction was performed using Chang's method.

Image analysis

The image data were analyzed using SPM96. Prior to statistical analysis, all of the images were spatially normalized into the standard template developed by Ohnishi et al. to remove the inter-subject anatomical variability.¹¹ Statistical parametric maps, which are spatially extended



a



b Comparison of rCBF between transient hypothyroidism (whole patients) and control

Fig. 1 SPM map showing significantly lower rCBF in transient hypothyroidism in comparison with healthy volunteers. Notice the decrease of rCBF in the posterior part of the bilateral parietal lobe, right temporal lobe and bilateral cuneus (a). Compared to the normal control, patients with transient hypothyroidism demonstrated relatively decreased global rCBF. However, it was not statistically significant. They also showed relatively lower rCBF in prefrontal area, temporal lobe, parietal lobe and occipital lobe (b).

statistical processes, were used to characterize regionally specific effects in imaging data. We used the adjusted rCBF images (normalization of global CBF for each subject to 50 ml/100 g/min with proportional scaling) to evaluate the alteration of the relative rCBF distribution in the transient hypothyroidic patients. The resulting set of values for each comparison constituted a statistical parametric map of the t statistic SPM {t}. The SPM {t} maps were then transformed to the unit of normal distribution (SPM {z}) and reached a threshold at $p = 0.01$. The resulting regions were examined using multiple comparisons. The significance of each region was estimated at a threshold of $p = 0.01$ using distributional approximations from the theory of Gaussian fields.¹² Anatomic localization was done according to the atlas of Talairach and Tournoux¹³ using a set of linear transformations.¹⁴ At the same time, the absolute value of rCBF was also analyzed in a transient hypothyroidism condition. Global rCBF of the cerebrum was calculated by the Patlack plot analysis, and the rCBF of each territory was obtained using 3D-SRT software developed by Takeuchi, et al.¹⁵ In the statistical analysis, we used the non-parametric Kruskal-Wallis test to assess the difference between each group. A p value of < 0.05 was considered to be significant.

The analyzed issues were as follows.

(1) To elucidate the influence of induced hypothyroidism on rCBF alteration, a group comparison of rCBF distribution between the transient hypothyroidic patients ($n = 24$) and the healthy volunteers ($n = 15$) was performed using SPM. The absolute values of global rCBF and rCBF in 4 territories (pre-frontal, parietal, temporal and occipital) between all hypothyroidism patients and normal controls were also compared.

Table 1 Hypothyroidism vs. control subjects

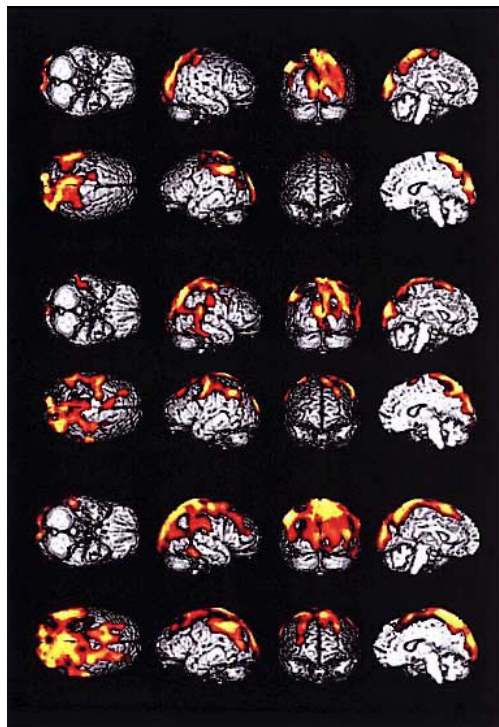
Anatomical location	Maximal Z score
Left. inferior parietal lobule	5.6
Right. precuneus	5.6
Left. cuneus	5.3

Table 2 The severity of depression and rCBF pattern

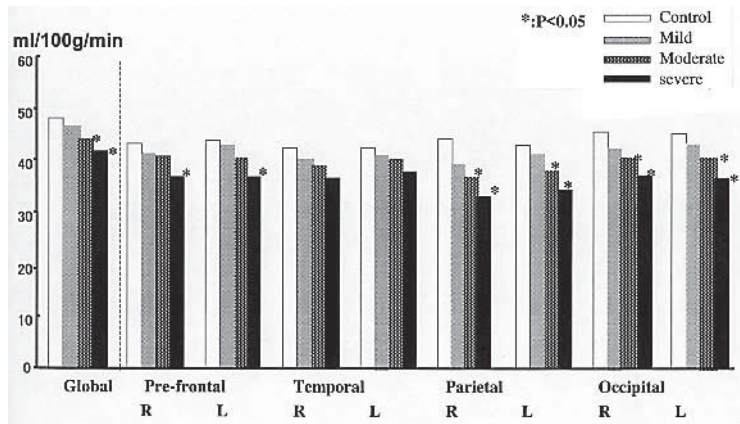
Depression	Anatomical location	Maximal Z score
Mild ($n = 8$)	Left. cuneus	4.63
	Right. inferior occipital gyrus	4.46
	Left. inferior parietal lobule	4.31
Moderate ($n = 9$)	Left. inferior parietal lobule	5.41
	Right. paracentral lobule	5.06
	Left. paracentral lobule	4.97
Severe ($n = 7$)	Right. precuneus	4.72
	Left. cuneus	4.69
	Right. paracentral lobule	4.05

(2) To analyze the possible association between the severity of depression and rCBF alteration, a comparison of rCBF distribution between the healthy volunteers and each subgroup (severe, moderate and mild case of depression) classified by depression score (SDS) was conducted. In addition, the absolute rCBF value between normal controls and each subgroup was also compared.

(3) To evaluate the serial rCBF change individually, the Jack-knife test was done by comparing the data with the healthy volunteers before and after thyroid hormone replacement. Based on the results, all cases were categorized into three subgroups, namely, improved, unchanged and normal. The improved group is composed of patients



a



b Comparison of rCBF between transient hypothyroidism (subgroup) and control

Fig. 2 With an increase in the severity of depression, a significant hypo-perfusion area extended to the prefrontal cortex. Every subgroup showed a significant reduction of rCBF in the bilateral precuneus, cuneus, and inferior parietal lobe (*Upper row*: mild stage group, *Middle row*: moderate stage group, *Lower row*: severe stage group) (a). In a comparison of the subgroups with transient hypothyroidism and normal control, both the moderately and severely depressed individuals showed significantly decreased global rCBF. They also demonstrated a significant rCBF reduction in the parietal lobe and occipital lobes. Significantly decreased rCBF in the prefrontal area was also noted in the severely depressed patients (b).

who improved and attained the same rCBF levels as those in the normal controls after thyroid hormone replacement. The unchanged group included patients with significantly decreased rCBF on the baseline study who still showed significant hypo-perfusion after thyroid hormone replacement. The normal group included patients whose rCBF did not show any statistical significance compared with normal controls in the baseline study and in the follow-up study after thyroid hormone replacement.

(4) To confirm the possible reversibility of rCBF alteration after thyroid hormone replacement, a group comparison study between the normal controls and the improved group was done before and after thyroid hormone replacement. Similarly, a group comparison test between the unchanged group and the normal controls was also performed.

(5) Finally, to determine the clinical factors that were influential for the reversibility of rCBF, the mean value of age, T3, T4, TSH, SDS score, and duration between the serial studies were compared among the three subgroups of patients (improved, unchanged and normal).

RESULTS

(1) Transient hypothyroidic patients revealed a significant decrease in rCBF in the parietal (inferior parietal gyrus and precuneus) and the occipital lobes (cuneus) (Fig. 1a, Table 1). The global absolute rCBF was relatively lower but not statistically significant in transient

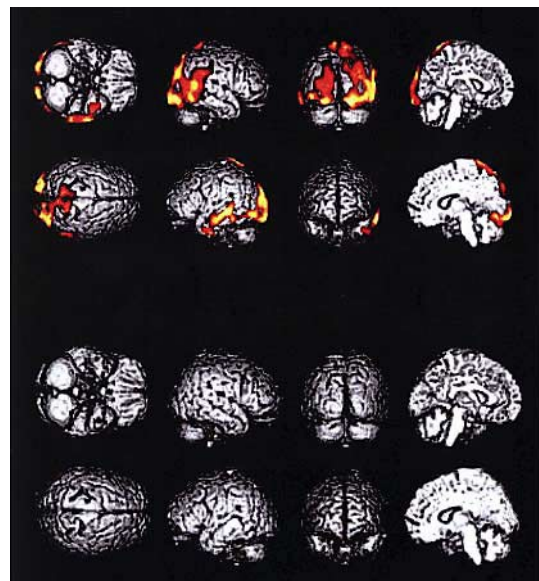

Fig. 3 Forty-five-year-old woman. Improved case. Serum T3, T4, and TSH (0.4 ng/ml, 1.8 μ g/dl, 120 μ IU/ml) changed to the normal range (1.1 ng/ml, 10.3 μ g/dl, 0.1 μ IU/ml) after thyroid hormone administration. On the 99m Tc-HMPAO SPECT using SPM analysis by the Jack-knife test, there was significantly decreased rCBF in the bilateral posterior lobe, posterior lobe, and bilateral superior temporal lobe in the hypothyroidic condition (*upper*). These decreased rCBF area improved after thyroid hormone therapy (*lower*).

hypothyroidic patients compared to that in normal controls. The regional rCBF in prefrontal region, temporal, parietal and occipital lobes also showed no statistical significance between the hypothyroidic patients and normal controls either (Fig. 1b).

(2) In the group with a mild stage depression, significant hypoperfusion areas were noted in the left cuneus and in the bilateral posterior part of the parietal lobe and part of the bilateral temporal lobes. Similarly, the bilateral posterior part of the parietal lobe was also noted as a significant hypoperfusion area in the group with moderate depression. In the group with severe depression, significant hypoperfusion areas extended to the bilateral prefrontal areas in addition to the left cuneus and bilateral posterior-part of the parietal lobe. The significantly decreased rCBF area extended to the prefrontal area as the severity of depression advanced (Table 2, Fig. 2a). The result was quantitatively confirmed by the absolute value. Within the hypothyroidism subjects, both groups, those with severe and moderate depression, showed significantly lower rCBF of the global, bilateral parietal, and bilateral occipital lobes than did those in the normal control group. Significant rCBF reduction in the prefrontal area was also noted in the severely depressed patients (Fig. 2b).

(3) Nine of 24 patients (37.5%) were categorized as improved (Fig. 3). Seven of 24 patients (29.2%) were unchanged, and the normal group had 8 (33.3 %) patients

(Table 3).

(4) The improved group showed significantly reduced rCBF of the bilateral parietal lobes and occipital lobe in the hypothyroidic condition. After thyroid hormone replacement, these abnormal rCBF area disappeared (Table 4, Fig. 4). In contrast, in the unchanged group, a significant hypoperfusion area became localized but remained after thyroid hormone replacement (Table 4, Fig. 5).

(5) In comparison study (unpaired t-test) between the improved group and the unchanged group, there was no statistical significance in the mean value of age, T3, T4, TSH, and SDS score, and duration between the serial studies (Table 5).

Table 3 Subgroup according to the effect of thyroid hormone replacement

· The improved group:		
Decreased rCBF with improvement after thyroid hormone replacement	n = 9	(37.5%)
· The unchanged group:		
Decreased rCBF with no significant change after thyroid hormone replacement	n = 7	(29.2%)
· The normal group:		
No abnormalities in hypothyroidism condition	n = 8	(33.3%)

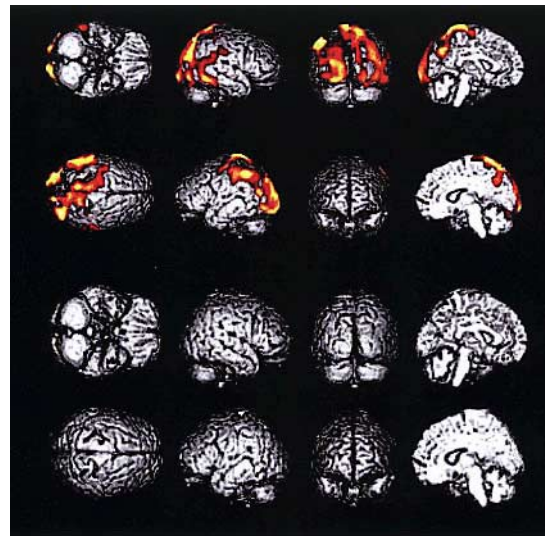


Fig. 4 Tc-99m-HMPAO SPECT with SPM analysis in patients with the improved group. In the hypothyroidic condition (*upper*), there was significantly decreased rCBF in the bilateral parietal and bilateral occipital lobes. These decreased rCBF areas improved and disappeared after thyroid hormone replacement (*lower*).

Table 4 Comparison between the improved group and unchanged group

	Anatomical location	Maximal Z score
Improved group (n = 9)		
Hypothyroidic condition	Left inferior parietal lobule	4.75
	Right precuneus	4.44
	Right cuneus	4.38
Unchanged group (n = 7)		
Hypothyroidic condition	Right supra marginal gyrus	4.68
	Right inferior parietal lobule	4.47
	Left cuneus	4.38
Euthyroidic condition	Left cuneus	4.16
	Right cuneus	3.96
	Right precuneus	3.87

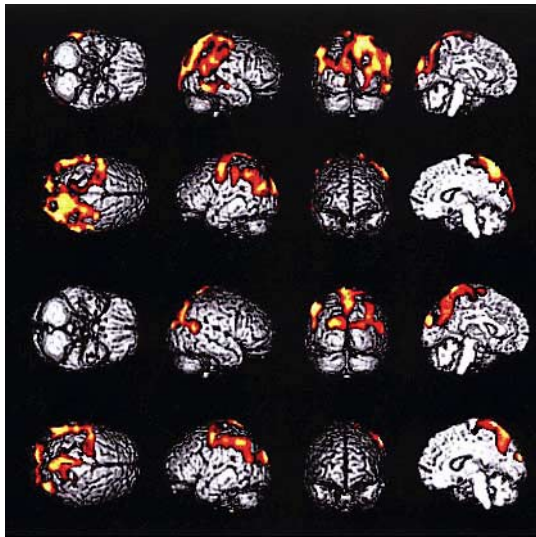


Fig. 5 Tc-99m-HMPAO SPECT with SPM analysis in patients in the unchanged group demonstrated persistently decreased perfusion in both the parietal and occipital lobes even after thyroid hormone replacement therapy (*upper*). However, these significantly low perfusion areas became localized and decreased more in size than those in condition with transient hypothyroidism (*lower*).

Table 5 Comparison of clinical factors

	Improved group (n = 9)	Unchanged group (n = 7)	Normal group (n = 8)
Age (y)	53.8 ± 17.3	57.6 ± 5.3	52.6 ± 7.7
T3 (ng/ml)	1.3 ± 0.7	1.1 ± 0.8	1.1 ± 0.8
T4 (μg/dl)	10.3 ± 3.7	9.3 ± 3.3	10.2 ± 2.3
TSH (μIU/ml)	0.2 ± 0.08	0.3 ± 0.07	0.3 ± 0.06
Interval (day)	77.3 ± 32.1	66.5 ± 28.3	/
SDS change	8.4 ± 2.4	7.5 ± 2.6	/

T3, T4, TSH: Mean values at follow-up study

Interval: Mean intervals from the baseline study

SDS change: Change of the depression score value between the serial studies

DISCUSSION

The current study showed a significant decrease in rCBF by SPM analysis in the short duration of induced transient hypothyroidism before ^{131}I -therapy. In the quantitative analysis, the reduced rCBF was noted in the bilateral parietal, occipital and frontal lobes in patients with moderate or severe depression. The result agrees partially with a previous report regarding the decrease of rCBF in induced hypothyroidism by a PET study.⁷

Mental condition is a major factor in determining rCBF distribution.^{6,16,17} Patients with hypothyroidism are more depressed than those with euthyroidism. Previous reports have indicated that depression induces a reduction in

rCBF in the left anterior cingulate and left dorsolateral prefrontal cortex.^{18,19} However, in the current study, most patients showed significant hypoperfusion in the inferior parietal lobe, precuneus, cuneus. They did not show significant hypoperfusion in the frontal lobe or anterior cingulate gyrus related to depression. The result agrees partially with a report by Constant et al., in which they refer to a trend toward reduced glucose metabolism in the inferior parietal lobe.⁷ The parieto-occipital lobe is one of the regions associated with the organization of language when listening, speaking, or writing. The psychiatric manifestations of hypothyroidism have many aspects, including psychomotor slowing,²⁰ depression,²¹ and anxiety.²¹ Cognitive dysfunctions with alterations in attention, concentration, perception, and speed of thought were also common clinical manifestations.²² As no patients were subjected to cognitive examinations, such as the mini mental state examination (MMSE), the exact cause of low perfusion in these areas could not be validated. Although symptoms were not always manifested, a few patients complained of impaired reading or writing ability. However, latent cognitive dysfunctions might exist in an induced hypothyroidic condition. Significant reduction of rCBF in the posterior part of the parietal lobe should be associated with cognitive dysfunctions. A cognitive function test or SPECT with a cognitive function task might be preferable to validate the relationship to the change of rCBF.

Both precuneus and cuneus play a role in vision-related functions. However, no patients revealed visual dysfunctions, such as hallucinations or optic ataxia.²³ In previous research, a trend has been reported toward reduced rCBF and reduced glucose metabolism in the left cuneus at a lower statistical level.⁷ A detailed study of visual activity and perception in hypothyroidism, combined with a neurochemical and neuropathological study of the cortex related to visual ability, is required.

Interestingly, there was no significant reduction of rCBF in the prefrontal area, although these changes are usually described in depressed patients. On the other hand, the reduced rCBF area was larger in the severely depressed group than in other groups, and these low perfusion area tended to extend to a part of the prefrontal area in individuals in the severely depressed group. As described above, latent cognitive dysfunction should be related to these phenomena. The depressive state might be induced secondary by these cognitive dysfunctions. Therefore, the positive association between the prefrontal rCBF and the severity of the SDS score was partially considered. Because the depression of the subjects in the current study was relatively mild, the prefrontal area was assumed to be preserved in the group comparisons between all the subjects and the normal controls. A respective subgroup comparison according to the SDS score was preferable to confirm the association between depressive symptoms and the rCBF change in the prefrontal cortex in

induced transient hypothyroidism.

The insignificant rCBF improvement in about one-third of the patients after thyroxine replacement suggests that thyroid hormone replacement therapy is ineffective for the recovery of rCBF alteration during the short term. The current result was partly supported by a report from Pollock et al., which showed that thyroxine did not restore cognitive function.²⁴ However, these results are in contrast with previous studies, in which thyroxine treatment was associated with psychological improvement.^{6,12,16,17}

One possible explanation of the result is the severity of the patients' hypothyroidism. Clinically apparent psychiatric conditions in severe hypothyroidism were improved by thyroxine.⁶ However, a slight modification in the subclinical psychiatric condition, such as in the current study, might not be detected. On the other hand, by the Jack-knife test, 56.3% of the cases showed improvement to some extent after thyroxine replacement. Although the effective factor could not be determined, age and the duration of the thyroxine replacement period were considered to be related. In addition, repetitive induced hypothyroidism could cause severe neuronal damage. The amount of ¹³¹I therapy, therefore, could also be an influential factor.

About one third of all the subjects showed a normal rCBF range under the hypothyroidic condition. Although no prominent characteristics were found, most of these subjects included relatively, but not significantly, younger patients. Aging might be the determining factor in the reduction of rCBF in transient hypothyroidic conditions. This speculation needs to be confirmed in a comparison study with a larger group of age-matched controls.

Although we used the normalized rCBF to remove the differences in global CBF between the individuals, there are some possible disadvantages to using SPM96 in SPECT image analysis, which include its lack of validation and the limited number of scans involved in a typical SPECT study (often less than 30). As a result, some studies may not have sufficient statistical power to accurately control for a false negative result in areas showing no significant differences between patients and controls.²⁵ Although the SPM technique is useful for objective investigations, further analysis in a larger population will clarify the issue. At the same time, to prevent the confounding factor of primary psychiatric disease, a pre-operative SPECT scan would have improved the study design with a better comparison.

In the normalization process of all subjects prior to statistical analysis, we used the ECD template.¹¹ The rCBF distribution is different between ECD and HMPAO in the same standard brains, namely, HMPAO SPECT showed relatively higher uptake in the medial temporal lobes, thalami, periventricular white matter.²⁶ However, anatomical distribution is almost the same between the two radiopharmaceuticals. Therefore, statistical analysis in the standard brain, smoothed and globally normalized

in the same template was considered to be possible. However, Gispert et al. reported that using the standard template with different tracer may lead to inconsistent interpretations of the SPM analysis.²⁷ Ideally, a standard template with HMPAO should be used for strict analysis.

In addition, HMPAO has the limitation of soft tissue, which causes contamination by scattering X-rays. In particular, a tumor or inflammation of extra-cranial skin tissue may cause a localized increased uptake.²⁸ Although there were no cases in the current study of cases with a high tracer uptake in extra-cranial skin tissue, the influence of the background could not be ignored. Tracers with a small background, such as ECD, would be preferable in future research.

One more issue is the influence of hypothyroidism on cardiac contractility.²⁹⁻³¹ Because rCBF is affected by cardiac functions,³²⁻³⁴ the current data could not exclude the influence of impaired cardiac contractility. However, all of the patients underwent a whole body MIBI scintigraphy to diagnose metastasis before I-131 therapy.³⁵ Because the MIBI-gated myocardial SPECT performed at the same time showed normal left ventricular wall motion and normal LVEF value in all cases, it was assumed that there was no influence of hemodynamic failure. Future study should include a categorization of cases according to myocardial functions.

CONCLUSION

The current study demonstrated that there was a significant decrease of rCBF in transient hypothyroidism in the bilateral precuneus, inferior-parietal lobe, and cuneus in comparisons with healthy volunteers. As the severity of depression in transient hypothyroidism advanced, these decreased rCBF area extended to the frontal lobe. The results suggested that both depression and cognitive dysfunction influenced the rCBF alteration.

After thyroid hormone replacement, some cases revealed prominent rCBF improvement, others showed fixed or prolonged decreased rCBF. Recovery of rCBF in transient hypothyroidism after total thyroidectomy, therefore, may be dependent on individual characteristics during a short-time period.

Additional studies are needed to confirm whether the current results are applicable to other hypothyroidic conditions.

ACKNOWLEDGMENTS

This work was supported in part by the Grant-in-Aid for Scientific Research (#12670890) of Japan Society for the Promotion of Science.

The authors thank the technical staff for their assistance, Hideo Arita and Keishi Takayama at Miyazaki Medical College for data acquisition, and Yoshihiro Tahara for developing the figures.

REFERENCES

- Whybrow PC. The therapeutic use of Triiodothyronine and high dose thyroxine in psychiatric disorder. *Acta Med Austriaca* 1994; 21: 44–47.
- Jackson I. The thyroid axis and depression. *Thyroid* 1998; 8: 951–956.
- Haggerty JJ, Evans DL, Prange AJ. Organic brain syndrome associated with marginal hypothyroidism. *Am J Psychiatry* 1986; 143: 785–786.
- O'Brien MD, Harnis PH. Cerebral-cortex perfusion rates in myxedema. *Lancet* 1968; 1: 1170–1172.
- Madison L, Sensenbach W, Ochs L. Effect of hyperthyroidism and myxedema upon cerebral blood flow and metabolism. *Am J Med* 1951; 11: 246.
- Kinuya S, Michigishi T, Tonami N, Aburano T, Tsuji S, Hashimoto T. Reversible cerebral hypoperfusion observed with Tc-99m HMPAO SPECT in reversible dementia caused by hypothyroidism. *Clin Nucl Med* 1998; 24: 666–668.
- Constant EL, de Volder AG, Ivanoiu A, Bol A, Labar D, Seghers A, et al. Cerebral blood flow and glucose metabolism in hypothyroidism: A positron emission tomography study. *J Clin Endocrinol Metab* 2001; 86: 3864–3870.
- Colloby SJ, Fenwick JD, Williams ED, Paling SM, Lobotesis K, Ballard C, et al. A comparison of ^{99m}Tc-HMPAO SPET changes in dementia with Lewy bodies and Alzheimer's disease using statistical parametric mapping. *Eur J Nucl Med* 2002; 29: 615–622.
- Friston KJ, Holmes AP, Worsley KJ, Poline JB, Frith CD, Frackowiak RSJ. Statistical parametric maps in functional imaging: A general approach. *Hum Brain Mapp* 1995; 2: 189–210.
- Matsuda H, Tsuji S, Shuke N, Sumiya H, Tonami N, Hisada K. Noninvasive measurements of regional cerebral blood flow using technetium-99m hexamethylpropylene amine oxime. *Eur J Nucl Med* 1993; 20: 391–401.
- Ohnishi T, Matsuda H, Hashimoto T, Kunihiro T, Nishikawa M, Uema T, et al. Abnormal regional cerebral blood flow in childhood autism. *Brain* 2000; 123: 1838–1844.
- Friston KJ, Worsley KJ, Frackowiak RSJ, Mazziotta JC, Evans AC. Assessing the significance of focal activation using spatial extent. *Hum Brain Mapp* 1994; 1: 214–220.
- Talairach J, Tournoux P. *Co-Planar Stereotactic Atlas of the Human Brain*. Stuttgart, Germany; Thieme, 1988.
- Brett M. The MNI Brain and the Talairach Atlas. Available: www.mrc-Mrc-cbu.cam.ac.uk/Imaging/mnispace.html. Accessed January 16, 2002.
- Takeuchi R, Yonekura Y, Matsuda H, Konishi J. Usefulness of a three-dimensional stereotaxic ROI template on anatomically standardized ^{99m}Tc-ECD SPET. *Eur J Nucl Med* 2002; 29: 331–341.
- Bench CJ, Friston KJ, Brown RG, Frackowiak RS, Dolan RJ. Regional cerebral blood flow in depression measured by positron emission tomography: The relationship with clinical dimensions. *Psychological Medicine* 1993; 23: 579–590.
- Lucey JV, Costa DV, Blanes T, Busatto GF, Pilowsky LS, Takei N, et al. Regional cerebral blood flow in obsessive-compulsive disordered patients at rest. Differential correlates with obsessive-compulsive and anxious-avoidant dimensions. *British J Psychiatry* 1995; 167: 629–634.
- Bench CJ, Scott LC, Brown RG, Froston KJ, Frackowiak RSJ, Dolan R. Regional cerebral blood flow in depression determined by positron emission tomography. *J Cereb Blood Flow Metab* 1991; 11 (Suppl 2): S654.
- Baxter LR, Schwartz JM, Phelps ME, Mazziotta JC, Guze BH, Selin CE, et al. Reduction of prefrontal cortex glucose metabolism common to three types of depression. *Arch Gen Psychiatry* 1989; 46: 243–250.
- Dugbartey AT. Neurocognitive aspects of hypothyroidism. *Arch Intern Med* 1998; 158: 1413–1418.
- Boillet D, Szoke A. Psychiatric manifestations as the only clinical sign of hypothyroidism. A proposal of a case. *Encephale* 1998; 24: 65–68.
- Whybrow PC. Behavioral and psychiatric aspects of hypothyroidism. In: Braverman LE, Utiger RD, eds. *Werner and Ingbar's. The Thyroid*, 7th ed. Philadelphia; Lippincott-Raven, 1996: 866–869.
- Creem SH, Proffitt DR. Defining the cortical visual systems: "what," "where," and "how." *Acta Psychol* 2001; 107: 43–68.
- Pollock MA, Sturrock A, Marshall K, Davidson KM, Kelly CJ, McMahon AD, et al. Thyroxine treatment in patients with symptoms of hypothyroidism but thyroid function tests within the reference range: Randomised double-blind placebo controlled crossover trial. *BMJ* 2001; 323: 891–895.
- Acton PD, Friston KJ. Statistical parametric mapping in functional neuroimaging: Beyond PET and fMRI activation studies. *Eur J Nucl Med* 1998; 25: 663–667.
- Hyun IY, Lee JS, Rha JH, Lee IK, Ha CK, Lee DS. Different uptake of ^{99m}Tc-ECD and ^{99m}Tc-HMPAO in the same brains: analysis by statistical parametric mapping. *Eur J Nucl Med* 2001; 28: 191–197.
- Gispert JD, Pascau J, Reig S, Martinez-Lazaro R, Molina V, Garcia-Barreno P, et al. Influence of the normalization template on the outcome of statistical parametric mapping of PET scans. *Neuroimage* 2003; 19: 601–612.
- Carvalho PA, Schwartz RB, Alexander III E, Loeffler JS, Zimmerman RE, Nagel JS, et al. Extracranial metastatic glioblastoma: Appearance on thallium-201-chloride/Technetium-99m-HMPAO SPECT images. *J Nucl Med* 1991; 32: 322–324.
- Forfar JC, Muir AL. Left ventricular function in hypothyroidism. *Br Heart J* 1982; 48: 775–784.
- Crowley WF, Ridgway EC, Bough EW, Francis GS, Daniels GH, Kourides GS, et al. Noninvasive evaluation of cardiac function in hypothyroidism. Response to gradual thyroxine replacement. *N Eng J Med* 1977; 296: 1–6.
- Foldes J, Istvanfy M, Halmangyi M, Varadi A, Partos GO. Hypothyroidism and the heart. Examination of left ventricular function in subclinical hypothyroidism. *Acta Med Hung* 1987; 44: 337–347.
- Gruhn N, Larsen FS, Boesgaard S, Knudsen GM, Mortensen SA, Thomsen G, et al. Cerebral blood flow in patients with chronic heart failure before and after heart transplantation. *Stroke* 2001; 32: 2530–2535.
- Hagendorff A, Klemm E, Bangard M, Dettmers C, Wolpert C, Schumacher B, et al. Case report: regional cerebral hypoperfusion induced by ventricular tachycardia-short-term hippocampal hypoperfusion and its potential relationship to selective neuronal damage. *J Interv Card*

Electrophysiol 2001; 5: 435–441.

34. Hagendorff A, Kolsch C, Dettmers C, Hartmann A, Pfeiffer D, Luderitz B. Is brain blood supply affected by changes in cardiac volume? Measurements of brain blood supply in healthy subjects during volume overload and in patients with artificial pacemaker by changing the pacing rate. *Z Kardiol* 2001; 90: 35–42.
35. Nagamachi S, Jinnouchi S, Nishii R, Flores LG 2nd, Nakahara H, Futami S, et al. Evaluation of technetium-99m-MIBI scintigraphy in metastatic differentiated thyroid cancer-comparison study with ^{131}I and ^{201}Tl . *KAKU IGAKU (Jpn J Nucl Med)* 2000; 37: 89–98.