

Evaluation of asialoglycoprotein receptor imaging agent as a marker of hepatic ischemia-reperfusion injury and recovery

Hiroshi TOYAMA,* Kazuo SUZUKI,* Aiko NAITO,* Makoto KURODA,** Kaoru KIKUKAWA,* Yoshiyuki KOMORI,*** Akitake HASUMI,*** Kaname MATSUMURA,**** Toshiteru FUJIWARA,***** Kiyonobu ITO,***** Kazutaka EJIRI,* Kohei SENDA,* Akira TAKEUCHI* and Sukehiko KOGA*

*Department of Radiology, **Department of Pathology,
and ***First Department of Surgery, Fujita Health University, Toyoake
****Mie University, Tsu
*****Hokushin General Hospital, Nakano

Protection of hepatocytes from ischemia-reperfusion injury is a clinically important issue. The purpose of this study was to evaluate changes in acute liver damage and recovery after ischemia-reperfusion in rats with asialoglycoprotein receptor (ASGP-R) ligand. Ischemia was induced by clamping the hepatoduodenal ligament for 90 min. At 1, 3, 24, 48 hr, 1 and 2 wk after reperfusion, I-125-GSA was injected. Five min after injection, blood samples were obtained and the liver was removed. Several regions from each lobe were dissected, weighed and counted. Mean uptakes (% dose/g) in the liver and blood samples were calculated. Histologic sections stained with hematoxylin-eosin (H-E) stain showed ischemic damage at 1 and 3 hr, and focal hepatocyte necrosis at 24 hr. Predominant massive necrosis was not seen. The mitotic index with H-E stain and proliferating cell nuclear antigen (PCNA) labeling index were highest at 1 wk, indicating liver regeneration. At 1 and 3 hr, liver uptake was significantly decreased, and blood uptake was significantly increased, indicating decreased tissue blood flow and ischemic damage. Liver uptake showed significant increases at 48 hr and 1 wk, and was the highest at 1 wk, indicating liver regeneration during the convalescence stage. ASGP-R binding may provide valuable information on ischemia-reperfusion injury and recovery.

Key words: liver, asialoglycoprotein, ischemia and reperfusion injury, liver regeneration, ^{99m}Tc -DTPA-galactosyl human serum albumin (^{99m}Tc -GSA)

INTRODUCTION

THE HEPATIC ASIALOGLYCOPROTEIN RECEPTOR (ASGP-R) is responsible for rapid clearance of desialylated glycoproteins from the circulation by receptor-mediated endocytosis.¹ The marked accumulation of asialoglycoproteins in the serum of patients with liver disease is induced by a decrease in the amount of hepatic binding protein in the liver.²

Received November 30, 1998, revision accepted March 11, 1999.

For reprint contact: Hiroshi Toyama, M.D., Department of Radiology, Fujita Health University, 1-98, Dengakugakubo, Kutsukake, Toyoake, Aichi 470-1192, JAPAN.

E-mail: htoyama@fujita-hu.ac.jp

Tc-99m-DTPA-galactosyl human serum albumin (Tc-99m-GSA) is a ligand for ASGP-R, which is a hepatic cell surface receptor specific to galactose-terminated glycoproteins.^{3,4} Hepatic receptor imaging with Tc-99m-GSA is affected by hepatocyte function only, not by Kupffer cell function. Tc-99m-GSA permits numerical evaluation of the hepatic functional reserve by the receptor index, providing a more objective diagnosis than before.^{5,6} In Japan Tc-99m-GSA is already commercially available (Nihon Medi-Physics Co., Nishinomiya, Japan). The clinical significance of Tc-99m-GSA for hepatic functional reserve evaluation in chronic liver damage, fulminant hepatic failure and postoperative extended hepatic lobectomy has been reported.⁶⁻⁸

Protection of hepatocytes from ischemia-reperfusion injury is an important issue in the field of hepatic surgery

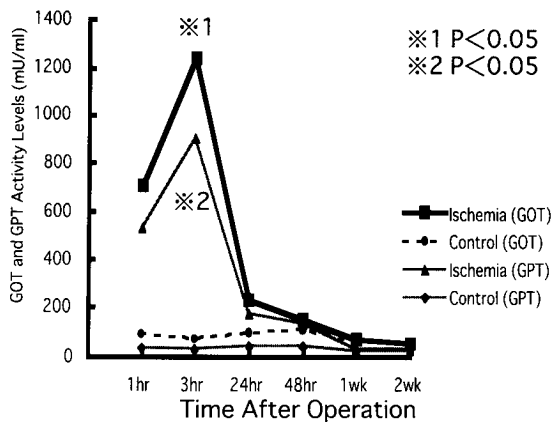


Fig. 1 Sequential changes of serum GOT and GPT in 90 min of hepatic ischemia and sham operated control.

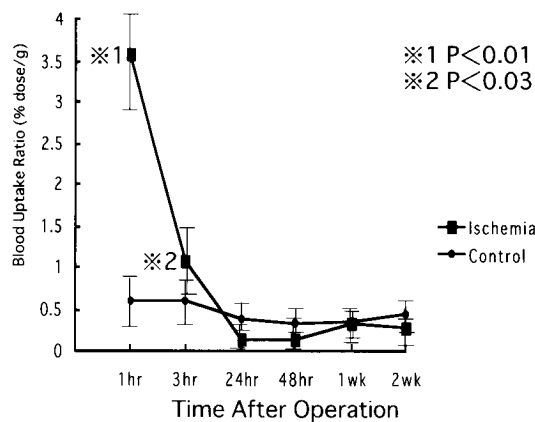


Fig. 3 Sequential changes of I-125-GSA blood uptake in 90 min of hepatic ischemia and sham operated control.

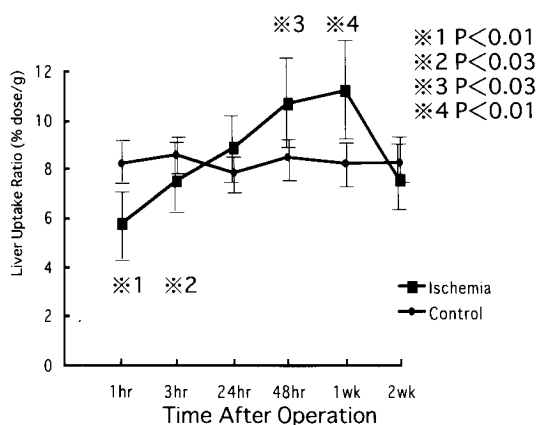


Fig. 2 Sequential changes of I-125-GSA liver uptake in 90 min of hepatic ischemia and sham operated control.

including liver resection and transplantation, and circulatory shock with resuscitation. Advances in these techniques have led to a steady increase in the number of such interventions. Prompt quantitative assessment of hepatic function and the patient's subsequent morbidity and mortality remain difficult despite the currently utilized historic markers of hepatic parenchymal injury.^{9,10}

The purpose of this study was to evaluate the significance of asialoglycoprotein receptor ligand in acute liver injury and recovery after ischemia-reperfusion in rats.

MATERIALS AND METHODS

1. Hepatic ischemia-reperfusion model

Adult male Wistar rats weighting 270 to 330 g were used. The rats were anesthetized with pentobarbital sodium (Nembutal) (0.09 g/kg intraperitoneally) and placed in the supine position. To induce hepatic ischemia, laparotomy was performed, then the hepatic artery, portal vein and bile duct at the hepatoduodenal ligament were exposed and cross-clamped for 90 min with a noncrushing mi-

crovascular clip. Reperfusion was started upon removal of the clip.

Sham-operated control rats underwent identical procedures, except that the cross-clamped clip was not applied.

2. Measurement of changes in I-125-GSA liver and blood uptake

At 1, 3, 24, 48 hr, 1 and 2 wk after reperfusion (3 rats, respectively), I-125-DTPA-galactosyl human serum albumin (GSA) (specific activity; 78.3 MBq/mg) (10.5 μ g/kg body weight) was injected via the tail vein. The injection dose of I-125-GSA was chosen as an appropriate dose for getting sufficient counts in each liver specimen. I-125-GSA was prepared and supplied by the Central Research Laboratory of Nihon Medi-Physics Co., Chiba, Japan. The radiochemical purity was 100%.

Five min after injection, a blood sample of approximately 0.5 ml was obtained by puncture of the inferior vena cava. Immediately after blood sampling, the inferior vena cava, abdominal aorta and left ventricle of the heart were cut. Then the liver was removed from the abdominal cavity.

Several regions from each lobe were dissected (6 samples in each rat except for the visually interpreted necrotic region), weighed and counted. Each sample was 0.2 to 0.3 g.

The amount in 100 μ l of blood (2 samples in each rat) obtained via the inferior vena cava was counted.

The mean uptakes (% dose/g) in 4 samples from the liver excluding the maximum and minimum count regions and blood samples were calculated at each time point.

The sham-operated control rats (3 rats, respectively) were measured by the same procedure at the same time points.

3. Measurement of serum GOT and GPT

In plasma samples obtained from the inferior vena cava as described above, serum GOT and GPT levels were mea-

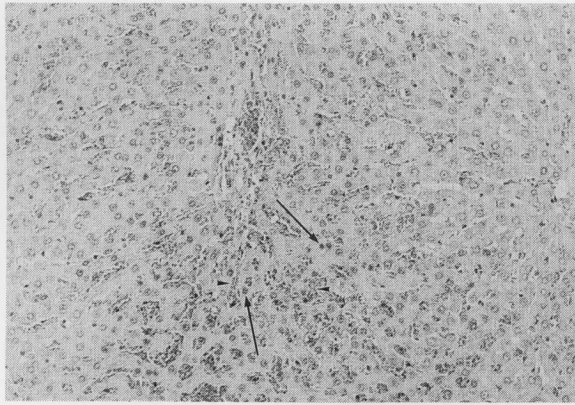


Fig. 4 At 3 hr after reperfusion in 90 min of hepatic ischemia, severe sinusoidal congestion (arrowheads) and hepatocellular pyknosis (arrows) from the periportal to midzonal areas are evident. (H-E; original magnification: $\times 200$)

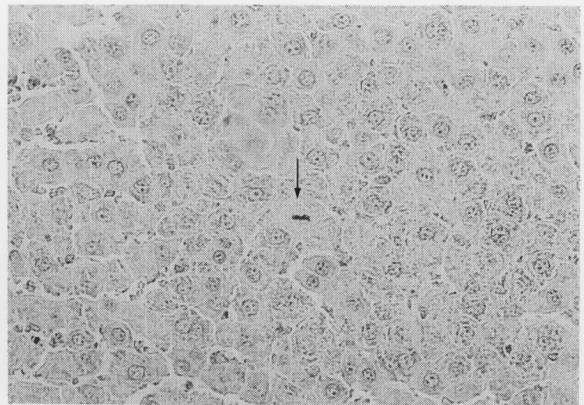


Fig. 6 At 1 wk after reperfusion in 90 min of hepatic ischemia, metaphase is shown (arrow). (H-E; original magnification: $\times 400$)

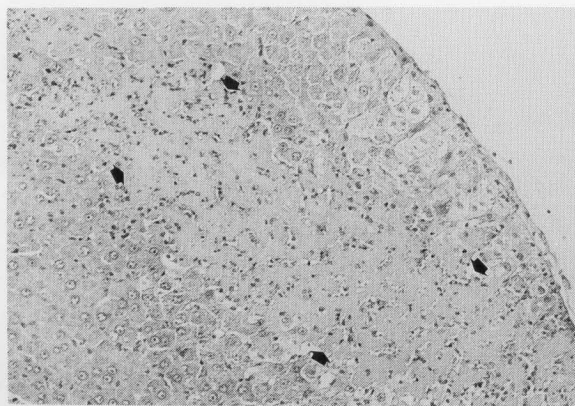


Fig. 5 At 24 hr, focal hepatocellular necrosis (arrows) is demonstrated in peripheral area. (H-E; original magnification: $\times 200$)

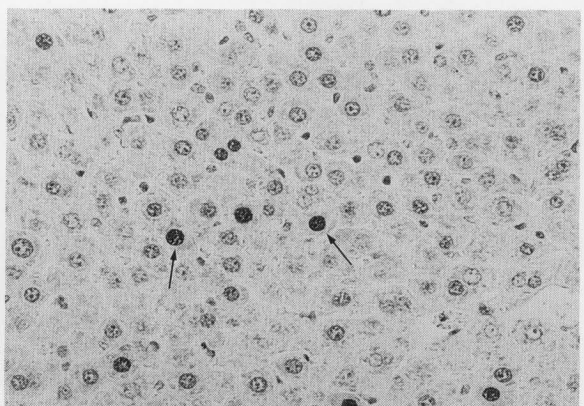


Fig. 7 At 1 wk after reperfusion in 90 min of hepatic ischemia, PCNA-positive cells are shown (arrows). (PCNA; original magnification: $\times 400$)

sured in the ischemia-reperfusion model and sham-operated control rats.

4. Histologic studies

In the surviving animals, at 1, 3, 24, 48 hr, 1 and 2 wk after reperfusion (3 rats, respectively), sections (5–10 mm) of the liver were fixed in 10% buffered formalin and then embedded in paraffin. Thin sections (5–10 μm) were prepared and stained with hematoxylin-eosin (H-E) stain for histologic assessment of ischemic damage and regeneration. Immunocytochemical staining was also performed with proliferating cell nuclear antigen (PCNA) for morphologic determination of liver regeneration.

PCNA positive cells were quantitated from 20 random 400 \times fields from 3 independent rats at each time point. The labeling index was expressed as the mean \pm S.D. positive nuclei per 100 nuclei (%). Mitosis of the nuclei was measured in 20 random 400 \times fields from 3 independent rats in the H-E stained sections. The mitotic index

was represented as the mean \pm S.D. number of metaphases per 100 cells (%).

5. Survival study

The rats were allowed to take food and water after recovering from anesthesia, and were followed up for survival for 2 wk.

6. Statistical analysis

The significance of any differences in statistical analyses, I-125-GSA uptakes and histologic studies was evaluated by Student's t-test. P values less than 0.05 were considered to be statistically significant.

RESULTS

1. Survival rate

Out of 36 rats, 12 (33.3%) died during occlusion or immediately after reperfusion, and 8 (22.2%) died within

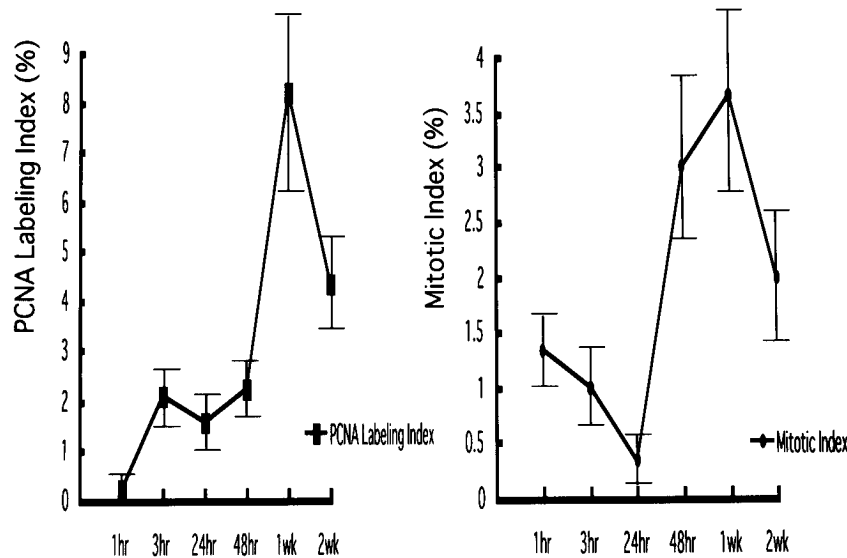


Fig. 8 Time course of the hepatic mitotic index (right) and PCNA labeling index (left) in 90 min of hepatic ischemia.

24 hr. Sixteen rats (44.4%) survived for 2 wk. No control rats had died at 2 wk.

2. Changes in serum GOT and GPT

The sham-operated control rats showed no increase in serum GOT or GPT at each time point (Fig. 1). At 3 hr after reperfusion, serum GOT and GPT showed a significant increase in comparison with the control values. Both GOT and GPT showed the highest increase at 3 hr.

3. Changes in I-125-GSA liver and blood uptake

The liver uptake of I-125-GSA was significantly decreased at 1 and 3 hr after reperfusion in comparison with the control values (Fig. 2). Liver uptake was lowest at 1 hr. Conversely, significantly increased liver uptake was seen in comparison with the control value at 48 hr and 1 wk. Liver uptake was the highest at 1 wk. The blood uptake of I-125-GSA was significantly higher at 1 and 3 hr than the control values (Fig. 3). Blood uptake was the highest at 1 hr.

4. Histopathologic changes

After 90 min of ischemia and 1 hr of reperfusion, sinusoidal congestion and hepatocellular pyknosis from the periportal to midzonal areas were evident. These changes were much more prominent at 3 hr after reperfusion (Fig. 4). There was no apparent focal hepatocellular necrosis at 1 or 3 hr after reperfusion. At 24 hr, focal hepatocellular necroses appeared in the midzonal and peripheral areas (Fig. 5).

Both the mitotic index and PCNA labeling index were the highest at 1 wk after reperfusion (Figs. 6–8).

No predominant massive hepatocellular necrosis was seen at 1 or 2 wk after reperfusion.

DISCUSSION

Several studies have reported two phases of liver injury after hepatic ischemia-reperfusion: an early phase that develops over the course of the first 1 to 3 hr after reperfusion, and a second, later phase that develops at 6 to 24 hr.^{9,11} The first hepatocellular injury that occurs during the first 1 to 3 hr postreperfusion is manifested by a rise in serum liver GOT levels. This early phase of injury is mediated through an oxygen-free radical mechanism, which is correlated with Kupffer cell activation. The later phase of injury that occurs between 6 and 24 hr postreperfusion is associated with a further rise in serum liver GOT. This later phase of hepatic reperfusion injury is associated with hepatic neutrophils. Liu et al. reported that in the case of reversible liver damage, GPT transiently increased and glycohydrolase activity levels decreased progressively, whereas GPT and glycohydrolase activity levels remained high and increased continuously when the liver injury was irreversible.¹⁰

Our results in surviving rats which showed transient serum GOT and GPT increase, early ischemic change and no expansion of hepatocellular necrosis indicated early phase and reversible liver damage. In the early phase at 1 and 3 hr after reperfusion, significantly decreased liver uptake of I-125-GSA indicating decreased ASGP-R binding, and significantly increased blood uptake indicating decreased blood clearance, were seen. The usefulness of Tc-99m-GSA in the estimation of liver injury immediately after ischemia-reperfusion has previously been reported in a rat model.^{12,13} These results indicate an absolute decrease in the total ASGP-R number due to hepatocellular necrosis and early synaptic damage.

Wakabayashi et al.¹⁴ reported that with a 30 min

ischemia and reperfusion model in rat liver, the tissue blood flow as monitored by a laser Doppler blood flow meter showed a gradual recovery until 120 min after reperfusion. To obtain an optimum plasma disappearance curve of Tc-99m-GSA, which was independent of changes in hepatic blood flow,¹⁵ Kouda et al.¹⁶ chose a higher dose (1665 µg/kg body weight) of Tc-99m-GSA. On the other hand, a much smaller dose (10.5 µg/kg body weight) was injected in our study to get reliable measurements, because of the higher count rate in the liver as opposed to the blood. The liver uptake of I-125-GSA at 1 hr was lower than the uptake at 3 hr, and the blood uptake of I-125-GSA at 1 hr was higher than the uptake at 3 hr. Decreased tissue blood flow in the early phase after reperfusion could also exaggerate the decrease in liver uptake and increase in blood uptake.

To evaluate the potential response to liver regeneration of ASGP-R in the liver after ischemia-reperfusion, we tried to correlate the levels of PCNA labeling index and mitotic index. After two-third hepatectomy in rats,¹⁷ the liver weight returned to normal by day 6.¹⁸ Rossi et al. reported with the same procedures that DNA synthesis reached its first peak at 22 hr, followed by a lower one at 45 hr. The mitotic index was the highest at 31 hr after the operation.¹⁹ Schlossberg et al. demonstrated with a lobar ischemia-reperfusion model in mouse liver that PCNA expression was high at 1 to 6 hr after liver reperfusion and returned to baseline levels by 20 hr in both ischemic and nonischemic lobes.¹¹ The transient significant increase in liver uptake of I-125-GSA seen in our experiments, which correlated well with the peaks of the PCNA labeling index and mitotic index, would be consistent with liver regeneration. A transient significant increase in liver uptake of I-125-GSA could also indicate a relative increase in surface ASGP-R (so-called 'upregulation'). On the other hand, however, previous *in vitro* studies^{18,20} as well as an *in vivo* study²¹ with an ASGP-R targeted hepatic magnetic resonance imaging agent showed a decrease in the surface ASGP-R number during hepatic regeneration after 70% partial hepatectomy in rats. Surface ASGP receptor binding in rats after partial hepatectomy showed an 80% decrease at 48 hr, and returned to normal by day 4.²⁰ This decrease was presumed to indicate the receptor-mediated endocytosis of desialylated glycoproteins. Recently, however, Kouda et al. reported that in the convalescent stage after hepatic injury and during recombinant human HGF stimulation, there was an associated increase in Tc-99m-GSA uptake per hepatocyte in an *in vivo* rat model.¹⁶ They speculated that augmented GSA uptake per hepatocyte during the convalescent stage after hepatic injury suggests a cellular compensation for the decreased number of hepatocytes. In our experiments, sequential changes in percent GSA uptakes per hepatic weight, actually per tissue, were also measured. Our results, which showed a transient increase in ASGP-R binding at 1 wk in the hepatic regeneration process, could be consistent with

their results. In human clinical studies, a transient increase in liver uptake of Tc-99m-GSA after transarterial embolization therapy (TAE)²² and hepatic resection^{8,23} showing regeneration of hepatocytes have been reported. Further sequential GSA as well as histologic studies from the early to later phase are warranted in the future.

In conclusion, the determination of ASGP-R binding with a specific tracer may provide a valuable measure of hepatic injury and recovery.

ACKNOWLEDGMENTS

The authors gratefully acknowledge Nihon Medi-Physics, Co., Ltd., for supplying I-125-GSA and Professor Hisahide Takahashi, Ph.D., Laboratory Animal Center, School of Medicine, Fujita Health University, for valuable suggestions and cooperation.

This paper was presented, in part, at the 7th World Congress of Nuclear Medicine and Biology between August 30 and September 4, 1998 in Berlin and the 38th annual meeting of the Japanese Society of Nuclear Medicine October 14–16, 1998 in Takamatsu.

REFERENCES

1. Spiess M. The asialoglycoprotein receptor: A model for endocytic transport receptors. *Biochemistry* 29: 10009–10018, 1990.
2. Sawamura T, Kawasato S, Shiozaki Y, Sameshima Y, Nakada H, Tashiro Y. Decrease of a hepatic binding protein specific for asialoglycoproteins with accumulation of serum asialoglycoproteins in galactosamine treated rats. *Gastroenterology* 81: 527–533, 1981.
3. Ha-Kawa SK, Tanaka Y. A quantitative model of Technetium-99m-DTPA-galactosyl-HSA for the assessment of hepatic blood flow and hepatic binding receptor. *J Nucl Med* 32: 2233–2240, 1991.
4. Kudo M, Todo A, Ikekubo K, Yamamoto K, Vera DR, Stadalnik RC. Quantitative assessment of hepatocellular function through *in vivo* radiotracer imaging with Tc-99m-galactosyl human serum albumin. *Hepatology* 17: 814–819, 1993.
5. Stadalnik RC, Vera DR, Woodle ES, Trudeau WL, Porter BA, Ward RE, et al. Tc-99m-NGA functional hepatic imaging: Preliminary clinical experience. *J Nucl Med* 26: 1233–1242, 1985.
6. Shiomi S, Kuroki T, Kuriyama M, Takeda T, Nishiguchi S, Nakajima S, et al. Evaluation of fulminant hepatic failure by scintigraphy with Technetium-99m-GSA. *J Nucl Med* 38: 79–82, 1997.
7. Kudo M, Todo A, Ikekubo K, Hino M. Receptor index via hepatic asialoglycoprotein receptor imaging: Correlation with chronic hepatocellular damage. *Am J Gastroenterology* 87: 865–870, 1992.
8. Toyama H, Ito K, Komori Y, Sugioka A, Shibata K, Komai S, et al. Evaluation of the residual functional reserve and the early regeneration after the hepatic resection using asialoglycoprotein receptor imaging agent. *KAKU IGAKU (Jpn J Nucl Med)* 32: 323–329, 1995.
9. Colletti LM, Kunkel SL, Walz A, Burdick MD, Kunkel RG, Wilke CA, et al. The role of cytokine networks in the local

- liver injury following hepatic ischemia/reperfusion in rat. *Hepatology* 23: 506–514, 1996.
10. Liu W, Schöb O, Pugmire JE, Jackson D, Zucker KA, Fry DE, et al. Glycohydrolases as markers of hepatic ischemia-reperfusion injury and recovery. *Hepatology* 24: 157–162, 1996.
 11. Schlossberg H, Zhang Y, Dudus L, Engelhardt JF. Expression of c-fos and c-jun during hepatocellular remodeling following ischemia/reperfusion in mouse liver. *Hepatology* 23: 1546–1555, 1996.
 12. Hashimura S, Kohno Y, Gohbara H, Nakagawa T, Shimizu M, Niiya H, et al. Quantitative evaluation of liver function using Tc-99m-GSA in rats with liver injury induced by ischemia-reperfusion. *Nippon Acta Radiologica* 52: 77–78, 1992.
 13. Gohbara H, Kohno Y, Sakae K, Satoh S, Shimizu M, Takeda Y, et al. Evaluation of usefulness of Tc-99m-GSA liver scintigraphy on hepatic ischemia-reperfusion injury in rats with obstructive jaundice. *Radioisotopes* 41: 407–410, 1992.
 14. Wakabayashi H, Karasawa Y, Tanaka S, Kokudo Y, Maeba T. The effect of FK506 on warm ischemia and reperfusion injury in the rat liver. *Surg Today* 24: 994–1002, 1994.
 15. Kawa S, Hazama H, Kojima M, Nishiyama Y, Nakazawa M, Hasegawa T, et al. A new liver function test using the asialoglycoprotein-receptor system on the liver cell membrane: II. Quantitative evaluation of labeled neoglycoprotein clearance. *KAKU IGAKU (Jpn J Nucl Med)* 23: 907–916, 1986.
 16. Kouda K, Ha-Kawa SK, Tanaka Y. Increased Tc-99m-GSA uptake per hepatocyte in rats with administration of dimethylnitrosamine or hepatocyte growth factor. *J Nucl Med* 39: 1463–1467, 1998.
 17. Higgins GM, Anderson RM. Experimental pathology of the liver. I. Restoration of the liver of the white rat following partial surgical removal. *Arch Path (Chicago)* 12: 186–202, 1931.
 18. Gärtner U, Stockert RJ, Morell AG, Wolkoff AW. Modulation of the transport of bilirubin and asialoorosomucoid during liver regeneration. *Hepatology* 1: 99–106, 1981.
 19. Rossi AM, Romano M, Zaccaro L, Pulci R, Salmona M. DNA synthesis, mitotic index, drug-metabolising systems and cytogenetic analysis in regenerating rat liver. Comparison with bone marrow test after 'in vivo' treatment with cyclophosphamide. *Mutation Research* 182: 75–82, 1987.
 20. Howard DJ, Stockert RJ, Morell AG. Asialoglycoprotein receptors in hepatic regeneration. *J Bio Chem* 257: 2856–2858, 1982.
 21. Leveille-Webster CR, Rogers J, Arias IM. Use of an asialoglycoprotein receptor-targeted magnetic resonance contrast agent to study changes in receptor biology during liver regeneration and endotoxemia in rats. *Hepatology* 23: 1631–1641, 1996.
 22. Kohda K, Ha-Kawa SK, Yamamoto R, Murata T, Harima K, Tanaka Y, et al. Change in lobar uptake of Tc-99m-galactosyl serum albumin after transarterial embolization therapy. *Nippon Acta Radiologica* 54: 1427–1429, 1994.
 23. Noguchi A, Hasegawa Y, Sasaki Y, Imaoka S, Hashizume T, Ibuka K, et al. Changes of liver function measured by Tc-99m-GSA scintigraphy after hepatectomy. *KAKU IGAKU (Jpn J Nucl Med)* 32: 419–426, 1995.