

Effects of diltiazem on myocardial perfusion abnormalities during exercise in patients with hypertrophic cardiomyopathy

Hiroki SUGIHARA,* Yoko TANIGUCHI,** Kazuki ITO,** Kouji TERADA,**
Katsushige MATSUMOTO,** Noriyuki KINOSHITA,** Akihiko AZUMA,**
Yo USHIJIMA,* Tomoho MAEDA* and Masao NAKAGAWA**

*Department of Radiology and **Second Department of Medicine, Kyoto Prefectural University of Medicine

The effect of diltiazem on myocardial ischemia in patients with hypertrophic cardiomyopathy (HCM) was evaluated by exercise myocardial ^{201}Tl single photon emission computed tomography (SPECT). Exercise myocardial SPECT was performed before and 8 weeks after oral administration of diltiazem (180 mg/day) in 20 patients with HCM who showed transient perfusion defects on exercise myocardial ^{201}Tl SPECT under control conditions. SPECT images were divided into 17 segments. The ^{201}Tl perfusion defects were visually scored and evaluated as the defect score. The transient dilation index was calculated as an index of subendocardial ischemia. Improvement of the defect score was demonstrated in 15 patients after the administration of diltiazem. The mean defect score decreased significantly from 9.90 ± 5.17 to 5.50 ± 4.89 ($p < 0.0001$). Although 16 of 20 patients showed an abnormal transient dilation index before diltiazem treatment, 16 showed improvement and 13 of these normalized after diltiazem therapy. The mean transient dilation index decreased from 1.16 ± 0.10 to 1.02 ± 0.09 ($p < 0.0001$). In conclusion, diltiazem prevents or diminishes myocardial ischemia in patients with HCM.

Key words: hypertrophic cardiomyopathy, exercise ^{201}Tl scintigraphy, myocardial ischemia, diltiazem

INTRODUCTION

RECENT STUDIES INDICATE that myocardial ischemia is a prominent feature of hypertrophic cardiomyopathy (HCM).^{1,2} Such myocardial perfusion abnormalities can be identified noninvasively by exercise ^{201}Tl single photon emission computed tomography (SPECT).^{3–6} Udelson et al.⁷ reported that the calcium channel blocker, verapamil may prevent or diminish inducible silent myocardial ischemia in patients with HCM. Some reports have also suggested that another calcium channel blocker, diltiazem is as effective or more effective than verapamil in improving subjective symptoms, exercise tolerance and left

ventricular hemodynamics in patients with HCM.^{8–10} We examined the effect of diltiazem on myocardial ischemia by means of exercise myocardial ^{201}Tl SPECT in patients with HCM.

METHODS

Subjects

The subjects were 20 patients with HCM who ranged in age from 19 to 68 years (mean 53). There were 17 male and 3 female patients. Seventeen patients had non-obstructive HCM and 3 had obstructive HCM. In each patient, HCM was defined as the echocardiographic demonstration of a hypertrophied, non-dilated left ventricle in the absence of another cardiac or systemic disease that itself could produce left ventricular hypertrophy. A Toshiba SSH 160A or Hewlett-Packard 77020AC ultrasound unit was used for echocardiographic imaging. M-mode and two-dimensional imaging were performed with the patients at rest in the left lateral decubitus position. The

Received August 6, 1998, revision accepted September 30, 1998.

For reprint contact: Hiroki Sugihara, M.D., Department of Radiology, Kyoto Prefectural University of Medicine, 465 Kajii-cho, Kawaramachi-Hirokoji, Kamigyo-ku, Kyoto 602-0841, JAPAN.

maximum wall thickness and left ventricular % shortening fraction were 21 ± 7 mm and $48 \pm 6\%$, respectively. All patients underwent coronary angiography, which disclosed normal coronary arteries. All patients showed transient ^{201}Tl perfusion defects on exercise myocardial ^{201}Tl SPECT. Patients who showed persistent ^{201}Tl perfusion defects or no defect were excluded from this study. The patients were given 180 mg diltiazem orally per day for a period of 8 weeks. Exercise myocardial ^{201}Tl SPECT was performed again at the end of the 8-week period.

Exercise myocardial ^{201}Tl SPECT

All patients underwent bicycle exercise according to a standard multi-stage exercise protocol with continuous monitoring of blood pressure and heart rate, blood pressure, ECG and symptoms. At peak exercise, 111 MBq of ^{201}Tl was injected intravenously. Exercise was continued for 1 minute to allow adequate circulation of the tracer. Ten minutes after exercise, SPECT was performed with a

digital gamma camera (Gammacamera 901A, Toshiba Co., Ltd., Japan) equipped with a low energy, high-resolution, parallel-hole collimator. The camera was rotated 180 degrees from the 45-degree left posterior oblique to the 45-degree right anterior oblique position. Thirty images were obtained in a 64×64 matrix, using 30 seconds of exposure for each 6-degree interval. Both exercise and 3-hour delayed images were obtained in this manner. After preprocessing the projection images with a Butterworth filter, reconstructed processing was performed with a Shepp-Logan filter without correction for attenuation or scatter. Data were reoriented to obtain the oblique angle tomograms parallel to the long axis and short axis of the left ventricle. The basal and midventricular segments on short axial views of the left ventricular myocardium were divided into 8 segments each, and 16 segments were taken. An apical region on the vertical long axis was also taken, and a total of 17 segments were analyzed (Fig. 1). The ^{201}Tl perfusion defects were visually evaluated by 2 experienced observers, with a 4-point grading system (0 = normal, 1 = mildly decreased uptake, 2 = moderately decreased uptake, 3 = defect). When they disagreed on the results, the grading was settled by consensus between 2 observers. The sum of the scores for all segments was used as the defect score. The cavity dilation on the early images caused by subendocardial hypoperfusion⁶ was quantified. The exercise/delayed ratio of the left ventricular cavity was named the transient dilation index (TDI).¹¹ Figure 2 shows the calculation of the TDI. Thirty-six radii at 10-degree intervals were generated from the center of middle myocardial images of the short axis. An area surrounded

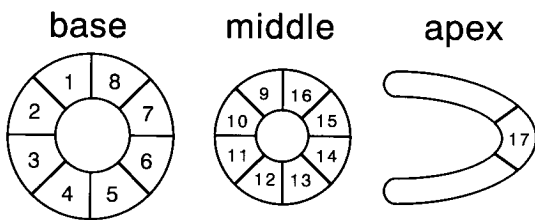


Fig. 1 Schematic representation of 17 regions on SPECT images. base = basal image of short axis, middle = middle image of short axis, apex = apex of vertical long axis

Transient Dilation Index

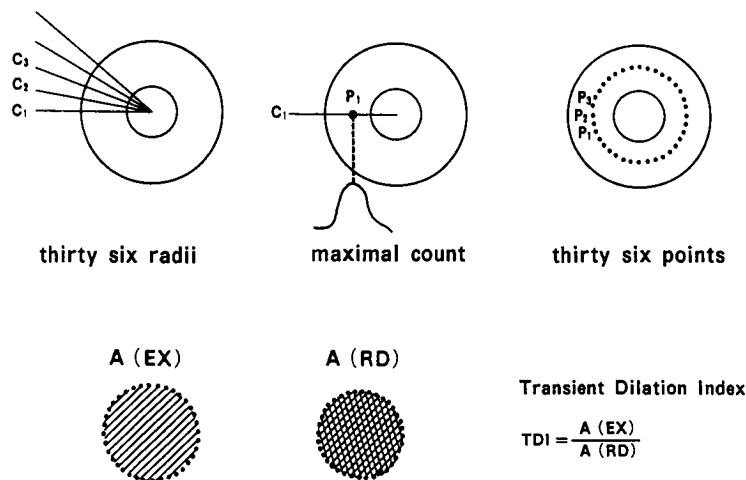


Fig. 2 Calculation of transient dilation index. Thirty-six radii at 10-degree intervals were generated from the center of the middle myocardial images of the short axis. An area surrounded by the 36 points of maximal count on each radius was defined in the initial and delayed images. The transient dilation index as an index of dilation was determined by dividing the area of the initial image by the area of the delayed image.

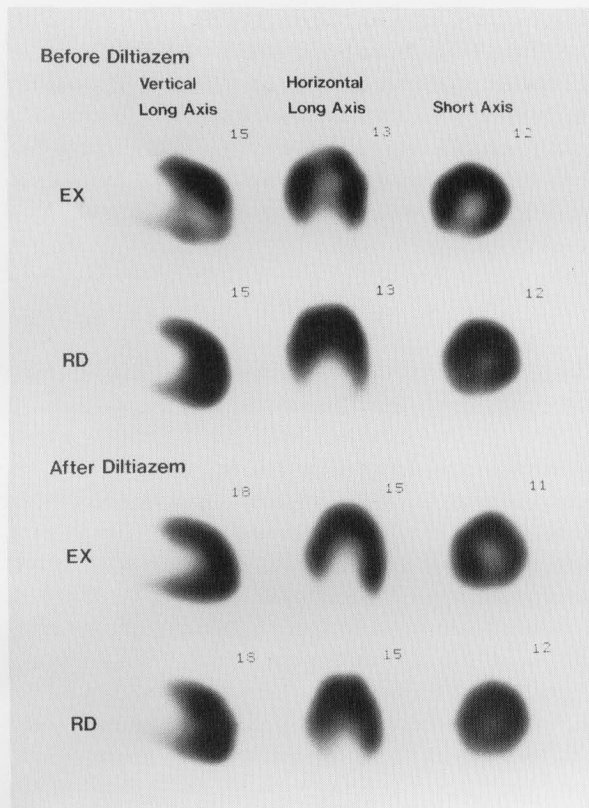


Fig. 3 Exercise ^{201}Tl SPECT images before (upper) and after diltiazem treatment (lower) in a 56-year-old man with hypertrophic cardiomyopathy. Before diltiazem administration, myocardial perfusion decreased in the septal portion of the posterior wall and the apex during exercise and redistribution is observed in these regions after 3 hours of rest. Myocardial perfusion improved in these regions during exercise after diltiazem treatment.

by 36 maximal count points on each radius was calculated in initial and delayed images. TDI as an index of relative dilation was determined by dividing the area in the initial image by the area in the delayed image. The defect score in the exercise images and TDI before and after the 8-week treatment with diltiazem were then compared. As mean + 2 standard deviation of TDI in 20 controls was 1.11, TDI > 1.11 was considered significant subendocardial ischemia.¹¹

Statistical analysis

All data are expressed as the mean \pm standard deviation. The differences between the mean values before and after diltiazem were analyzed with the paired t-test. A p value of less than 0.05 was considered to represent statistical significance.

RESULTS

1) Hemodynamic indices

Heart rate, blood pressure and rate pressure product at rest

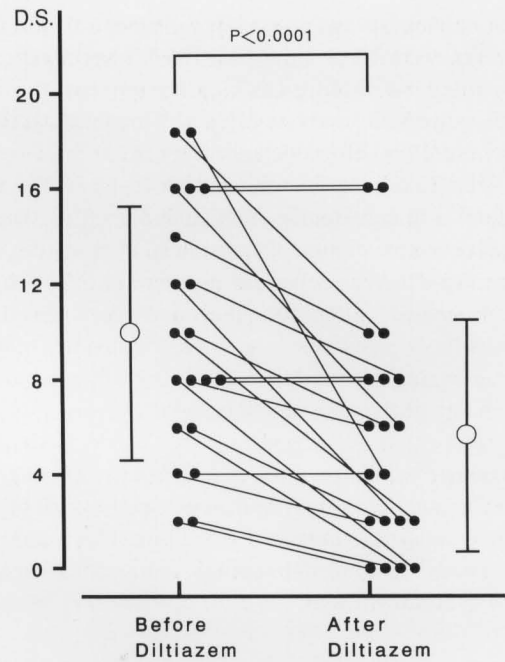


Fig. 4 Defect score before and after diltiazem administration. The defect score improved in 15 patients after diltiazem treatment. The mean defect score significantly decreased after diltiazem treatment. D.S. = defect score

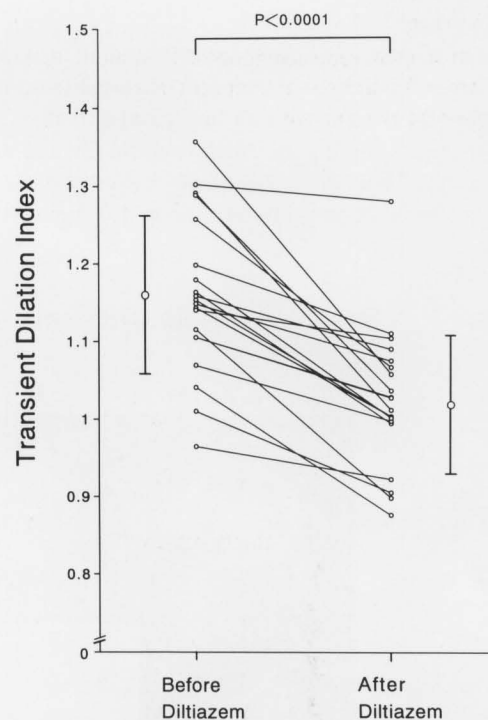


Fig. 5 Transient dilation index before and after diltiazem administration. Sixteen of 20 patients showed abnormal transient dilation indices (> 1.11) before diltiazem treatment, while 16 revealed improvement and 13 patients normalized after diltiazem treatment. Mean transient dilation index decreased significantly after diltiazem administration.

before and after diltiazem were (66 ± 5 beats/min, 139 ± 19 mmHg, $9.0 \times 10^3 \pm 1.2 \times 10^3$), (65 ± 7 beats/min, 137 ± 18 mmHg, $8.7 \times 10^3 \pm 1.0 \times 10^3$), respectively. Heart rate, blood pressure and rate pressure product at maximal stress before and after diltiazem were (131 ± 23 beats/min, 191 ± 29 mmHg, $25 \times 10^3 \pm 5.3 \times 10^3$) and (129 ± 23 beats/min, 198 ± 29 mmHg, $25 \times 10^3 \pm 5.9 \times 10^3$), respectively. The administration of diltiazem did not significantly change these indices either during exercise or at rest.

No patient discontinued the study due to hypotension or bradycardia. The pressure gradient calculated by Doppler echocardiography did not increase after diltiazem treatment in any of the obstructive cases.

2) Exercise tolerance, ECG change and symptoms

There was a significant difference in exercise time before and after diltiazem treatment (11 ± 2 min, 13 ± 3 min, $p < 0.01$). The maximal work rate significantly increased after diltiazem administration (98 ± 29 watts, 110 ± 28 watts, $p < 0.05$).

During exercise, ischemic ST-T changes appeared on ECG in 11 of 20 patients (55%) before diltiazem therapy and these changes improved in 8 of 11 patients (73%) after diltiazem treatment. Of the 5 patients who exhibited chest pain during exercise before diltiazem treatment, only 2 showed this symptom after treatment.

3) Exercise ^{201}Tl SPECT

Fifteen of 20 patients showed improvement in their defect score after 8 weeks of treatment with diltiazem. An example of 1 patient with an improved defect score is given in Fig. 3. Five patients showed no change in the defect score. There was a significant difference in mean defect scores before and after diltiazem treatment ($9.90 \pm$

5.17 , 5.50 ± 4.89 , $p < 0.0001$) (Fig. 4).

Although 16 patients showed abnormal TDI before diltiazem treatment, this index improved in all cases and normalized in 13 after diltiazem treatment. There was a significant difference in TDI before (1.16 ± 0.10) and after (1.02 ± 0.09) diltiazem administration ($p < 0.0001$) (Fig. 5). A typical example of 1 patient with normalized TDI is given in Fig. 6.

DISCUSSION

Myocardial ischemia may play an important role in the pathophysiology and the natural history of HCM.¹⁻⁶ Exercise ^{201}Tl myocardial SPECT has provided a non-invasive means of identifying myocardial perfusion abnormalities in HCM.³⁻⁶ Improvements in myocardial ischemia due to treatment may prevent a devastating outcome.¹² Both verapamil and diltiazem demonstrate negative inotropic action, negative chronotropic action, anti-arrhythmic effect, and peripheral and coronary artery dilation effects. The former has a stronger negative inotropic action than the latter. Previous studies have demonstrated the efficacy of verapamil and diltiazem in improving subjective symptoms, exercise tolerance and hemodynamics in patients with HCM. Toshima et al.⁸ reported that verapamil and diltiazem are equally effective for HCM in treating subjective symptoms and exercise tolerance. Udelson et al.⁷ and we¹³ reported that exercise induced myocardial perfusion abnormalities improved during verapamil treatment in the majority of HCM. Diltiazem and verapamil are commonly used Ca channel blockers in the treatment of HCM. However, it is not reported whether diltiazem improves or diminishes myocardial ischemia in patients with HCM. In this study,

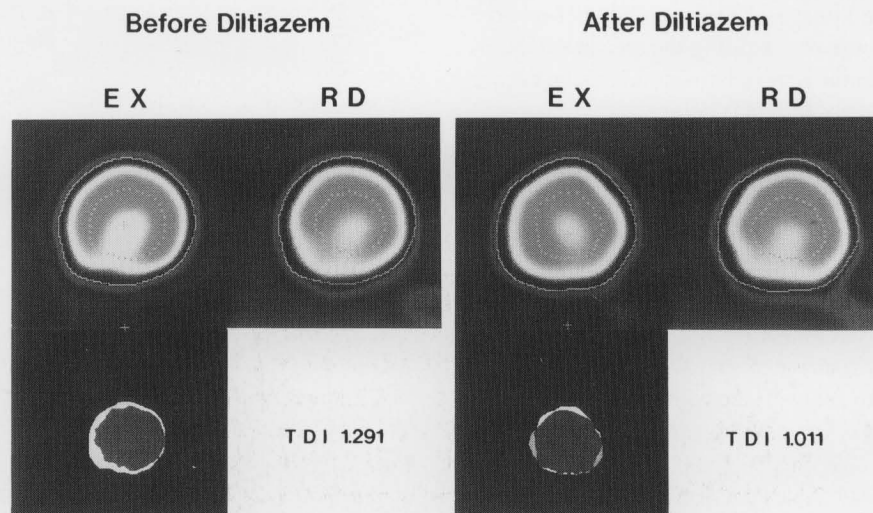


Fig. 6 Transient dilation index before (left) and after diltiazem treatment (right) in the same patient in Fig. 3. Transient dilation index decreased from 1.291 to 1.011 after diltiazem treatment. EX = exercise, RD = redistribution

we investigated the effects of diltiazem on myocardial ischemia in patients with HCM by means of exercise ^{201}Tl SPECT. O'Gara et al.⁶ interpreted the apparent cavity dilation in a ^{201}Tl study after exercise as being caused by subendocardial hypoperfusion. Cannon et al.¹⁴ reported that apparent cavity dilation during exercise ^{201}Tl scintigraphy may indicate ischemia-related changes in left ventricular filling, with an increase in diastolic pressure and endocardial compression. Consequently, not only the defect score, but also the TDI on exercise ^{201}Tl SPECT images was used as an index of subendocardial ischemia.¹³ Although TDI is not a "genuine" left ventricular cavity ratio between initial and delayed ^{201}Tl images, a decrease in ^{201}Tl uptake in the subendocardium during exercise caused by hypoperfusion would cause the points of maximal count to shift outwards. Therefore, TDI, which is easily calculated, was used as an index of transient cavity dilation. As mean + 2 standard deviation of TDI in 20 controls was 1.11, TDI > 1.11 was considered significant subendocardial ischemia.¹¹ After treatment with diltiazem, the exercise loading time and work rate significantly increased, similar to previous reports. The defect score and TDI decreased after treatment with diltiazem. The findings indicate that diltiazem reduced myocardial ischemia which occurred during exercise stress in patients with HCM.

Myocardial ischemia in HCM may result from several mechanisms, including intravascular and extravascular causes. The most important intravascular cause is abnormalities of the small, intramyocardial coronary arteries, characterized by thickened walls.¹⁵ Others include an inadequate capillary density relative to the increased myocardial mass^{16,17} and large or small coronary artery spasms.¹⁸ Extravascular causes include impaired left ventricular relaxation^{19,20} leading to a decrease in diastolic coronary blood flow and systolic compression of the septal perforator arteries.

Diltiazem has been shown to mitigate the effects of intravascular and extravascular causes. Firstly, it was reported that diltiazem improves impaired relaxation of the left ventricle in patients with HCM.¹⁰ This is due to a reduction in intracellular Ca overloading and an improvement in the asynchrony of contraction and relaxation of the left ventricle. Furthermore, through its negative inotropic effect, diltiazem reduces hyper-contraction of the left ventricle during exercise which increases myocardial oxygen demand. In this way, diltiazem improves myocardial ischemia in HCM. Secondly, diltiazem exhibits both dilating and anti-spastic effects on coronary arteries.²¹ These properties reduce the negative effects that intramural coronary artery disease and microvascular spasms may have on the coronary flow reserve. This, in turn, reduces subendocardial ischemia and improves impaired relaxation. Thus, diltiazem may reduce myocardial ischemia in patients with HCM by both intravascular and extravascular mechanisms.

It has been reported that Ca-channel blockers can increase the pressure gradient between the aorta and the left ventricle in obstructive cases, so it is necessary to observe patients during Ca-channel blocker administration. In this study, the pressure gradient calculated by Doppler echocardiography did not increase after diltiazem treatment in any of the obstructive cases.

Considering the natural history of HCM, it is important to investigate myocardial ischemia in HCM by exercise ^{201}Tl myocardial SPECT and to judge its improvement after diltiazem or verapamil administration. Whether diltiazem or verapamil is superior in preventing myocardial ischemia is difficult to determine. It is necessary to investigate the long term effects of diltiazem on myocardial ischemia in patients with HCM.

REFERENCES

1. Cannon RO, Rosing DR, Maron BJ, Leon MB, Watson SE, Epstein SE. Myocardial ischemia in patients with hypertrophic cardiomyopathy. Contribution of inadequate vasodilator reserve and elevated left ventricular filling pressure. *Circulation* 71: 234-243, 1985.
2. Thompson DS, Naquvi N, Juul SM, Swanton RH, Coltart DJ, Jenkins BS, et al. Effects of propranolol on myocardial oxygen consumption, substrate extraction, and hemodynamics in hypertrophic obstructive cardiomyopathy. *Br Heart J* 44: 488-498, 1980.
3. Pitcher D, Wainwright R, Maisy M, Curry P, Sowton E. Assessment of chest pain in hypertrophic cardiomyopathy using exercise Thallium-201 myocardial scintigraphy. *Br Heart J* 44: 650-656, 1980.
4. Hanrath P, Mathey DG, Montz R, Thiel U, Vorbringer H, Kupper W, et al. Myocardial Thallium-201 Imaging in Hypertrophic Obstructive Cardiomyopathy. *Eur Heart J* 2: 177-185, 1981.
5. Kenneth A, Morrison J, Padnick MB, Binder AJ, Chiaramida S, Margouleff D, et al. Idiopathic hypertrophic subaortic stenosis: Evaluation of anginal symptoms with thallium-201 myocardial imaging. *Am J Cardiol* 44: 1040-1045, 1979.
6. O'Gara PT, Bonow RO, Maron BJ, Damske BA, Lingen AV, Bacharach SL, et al. Myocardial perfusion abnormalities in patients with hypertrophic cardiomyopathy: Assessment with thallium-201 emission computed tomography. *Circulation* 76: 1214-1223, 1987.
7. Udelson JE, Bonow RO, O'Gara PT, Maron BJ, Lingen AV, Bacharach SL, et al. Verapamil prevents silent myocardial perfusion abnormalities during exercise in asymptomatic patients with hypertrophic cardiomyopathy. *Circulation* 79: 1052-1060, 1989.
8. Toshima H, Koga Y, Nagata H, Toyomasu K, Itaya K, Matoba T. Comparable Effects of Oral Diltiazem and Verapamil in the Treatment of Hypertrophic Cardiomyopathy. *Jpn Heart J* 27: 701-715, 1986.
9. Nagao M, Yasue H, Omote S, Takizawa A, Hyon H, Nishida S, et al. Diltiazem-induced decrease of exercise-elevated pulmonary arterial diastolic pressure in hypertrophic cardiomyopathy patients. *Am Heart J* 102: 789-790, 1981.

10. Suwa M, Hirota Y, Kawamura K. Improvement in left ventricular diastolic function during intravenous and oral diltiazem in patients with hypertrophic cardiomyopathy: An echocardiographic study. *Am J Cardiol* 54: 1047–1053, 1984.
11. Sugihara H, Shiga K, Umamoto I, Harada Y, Katahira T, Nakagawa T, et al. Assessment of transient dilation of the left ventricular cavity in patients with hypertrophic cardiomyopathy by exercise Thallium-201 scintigraphy. *KAKU IGAKU (Jpn J Nucl Med)* 27: 1281–1289, 1990.
12. Dilsizian V, Bonow RO, Epstein SE, Fananapazir L. Myocardial ischemia detected by thallium scintigraphy is frequently related to cardiac arrest and syncope in young patients with hypertrophic cardiomyopathy. *J Am Coll Cardiol* 22: 796–804, 1993.
13. Taniguchi Y, Sugihara H, Ohtsuki K, Umamoto I, Nakagawa T, Shiga K, et al. Effect of verapamil on myocardial ischemia in patients with hypertrophic cardiomyopathy: Evaluation by exercise thallium-201 SPECT. *J Cardiol* 24: 45–51, 1994.
14. Cannon RO, Dilsizian V, O'Gara PT, Udelson JE, Schenke WH, Quyyumi A, et al. Myocardial metabolic, hemodynamic, and electrocardiographic significance of reversible thallium-201 abnormalities in hypertrophic cardiomyopathy. *Circulation* 83: 1660–1667, 1991.
15. Maron BJ, Wolfson JK, Epstein SE, Roberts WC. Intramural ("small vessel") coronary artery disease in hypertrophic cardiomyopathy. *J Am Coll Cardiol* 8: 545–557, 1986.
16. Marcus ML, Harrison DG, Chilian WM, Koyanagi S, Inoue T, Tomanek RJ, et al. Alterations in the coronary circulation in hypertrophied ventricle. *Circulation* 75 (Suppl 1): 1–19, 1987.
17. Weiss MB, Ellis K, Sciacca RR, Johnson LL, Schmidt DH, Cannon PJ. Myocardial blood flow in congestive and hypertrophic cardiomyopathy, relationship to peak wall stress and mean velocity of circumferential fiber shortening. *Circulation* 54: 484–494, 1976.
18. Factor SM, Minase T, Cho S, Dominitz R, Sonnenblick EH. Microvascular spasm in the cardiomyopathic Syrian hamster: A preventable cause of focal myocardial necrosis. *Circulation* 66: 342–354, 1982.
19. Hanrath P, Mathey DG, Kremer P, Sonntag F, Bleifeld W. Effect of verapamil on left ventricular isovolumic relaxation time and regional left ventricular filling in hypertrophic cardiomyopathy. *Am J Cardiol* 45: 1258–1264, 1982.
20. Bonow RO. Effect of calcium-channel blocking agents on left ventricular diastolic function in hypertrophic cardiomyopathy and in coronary artery disease. *Am J Cardiol* 55: 172B–178B, 1985.
21. Weyrens FJ, Mooney J, Lesser J, Mooney MR. Intracoronary diltiazem for microvascular spasm after interventional therapy. *Am J Cardiol* 75: 849–850, 1995.