Annals of Nuclear Medicine Vol. 12, No. 2, 105–108, 1998

Gallium-67 scintigraphy in the treatment and prognosis of acute adult T-cell lymphoma

Leo G. FLORES II,* Shigeki NAGAMACHI,* Ryuichi NISHII,* Seishi JINNOUCHI,* Takashi OHNISHI,* Yoshio SHIMAO,** Katsushi WATANABE* and Shozo TAMURA*

*Department of Radiology and **Second Department of Pathology, Miyazaki Medical College*

The case of a 77-year-old male patient who complained of left upper quadrant pain and progressive vomiting. Laboratory examination showed extremely high lactic acid dehydrogenase (LDH) and adult T-cell leukemia antibody (ATLA). The anatomical studies CT, MRI, US and upper GI series substantiated an omental lymphadenopathy which was causing a circumferential compression of portions of the duodenum and jejunum. Gallium-67 citrate (Ga-67) scintigraphy showed high uptake at LUQ. Ultrasound guided biopsy failed to confirm the diagnosis. Irradiation was performed. Ga-67 scintigraphy had a contributory role in clinical subtyping of the disease, planning of treatment, posttreatment assessment and prognostication of adult T-cell lymphoma.

Key words: gallium-67 scintigraphy, adult T-cell lymphoma

INTRODUCTION

ADULT T-CELL LYMPHOMA (ATL) accounts for 43% of non-Hodgkin's lymphoma in Japan nationwide and 75% in Kyushu. More advanced clinicopathological features of ATL occur in southern Kyushu than in other districts so that the clinical course is short.[1,2] Although the role of Gallium-67 citrate (Ga-67) scintigraphy in the management of lymphoma is well established,[3] there are few reports on its use in acute ATL. Hoshi et al. reported that Ga-67 is effective in detecting malignant ATL lesions.[4] We present a case exhibiting additional application of Ga-67 scintigraphy in the management of acute ATL.

CASE REPORT

One month before admission, a 77-year-old male patient sought consultation for left upper quadrant pain. After investigation of the abdomen with computed tomography (CT) and ultrasonography (US), a tumor in the small intestine was suspected.

The patient was admitted after an episode of vomiting. Pertinent physical examination findings in the left upper quadrant of the abdomen, were slight tenderness on palpation and a barely palpable mass about fist size. There was no other palpable lymphadenopathy elsewhere in the body. Laboratory examination results were almost all within normal limits except for extremely high lactic acid dehydrogenase (LDH) and adult T-cell leukemia antibody (ATLA).

Upper gastrointestinal (UGI) series showed a circumferential compression of the third portion of the duodenum. Ultrasound of the abdomen exhibited a 2–3 cm multiple omental lymphadenopathy. CT of the abdomen confirmed the presence of an irregular mass of omental origin with heterogeneous enhancement that was surrounding the ligament of Treitz with concomitant ascites (Figure 1A). MRI of the abdomen similarly showed a 12 × 7 cm mass, probably lymphadenopathy, surrounding portions of the duodenum and jejunum. Varying signal intensities were noted on T1- and T2-weighted image and gadolinium-DTPA enhanced study. US guided biopsy was attempted few days after admission to confirm the diagnosis histologically, but it was unsuccessful.

Ga-67 scintigraphy was performed 72 hours after 111 MBq Ga-67 was administered intravenously. An Omega

Received September 8, 1997, revision accepted January 21, 1998.

For reprint contact: Leo G. Flores II, Department of Radiology, Miyazaki Medical College, 5200 Kihara, Kiyotake, Miyazaki 889–1692, JAPAN.

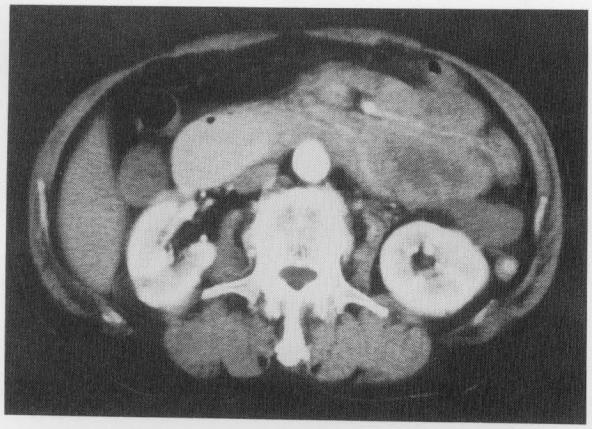

A

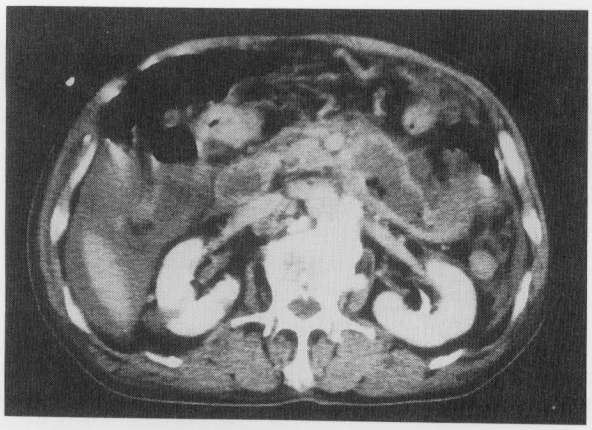

B

Fig. 1 Computed tomography images at the mid abdomen level, pretreatment image showing lymphadenopathy at the omentum (A) and posttreatment, omental lymphadenopathy showing decrease in size after treatment (B).

500 (Technicare) gamma camera with a medium-energy parallel collimator and Scintipac 700 data processor (Shimadzu, Kyoto, Japan) was used. Ga-67 scintigraphy showed a localized high uptake in the left upper quadrant (Figures 2A and B).

The localization with Ga-67 in the abdominal area only was the primary reason for the selection of radiotherapy as a form of management: a 1.5 gray dose (Gy)/day, 5 times a week with a total of 30 Gy.

After radiotherapy there was slight relief of symptoms. Repeat CT showed a decrease in the size with low density areas on the mass (Figure 1B). Thickening of the colon and bladder wall were noted (Figures 4A and B). There was increase in the severity of ascites with bilateral pleural effusion. Repeat Ga-67 scintigraphy showed no uptake in the areas included in the radiation field, but increase in uptake was noted in the left hypochondrium, right lumbar and hypogastrium regions (Figures 3A and B). Chemotherapy was reconsidered but could not be started due to hypercalcemia and deteriorating consciousness of the patient. The patient's condition progressively

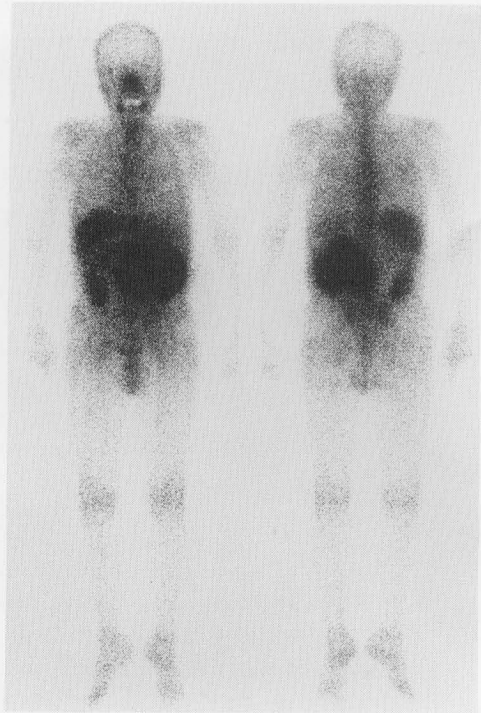

A

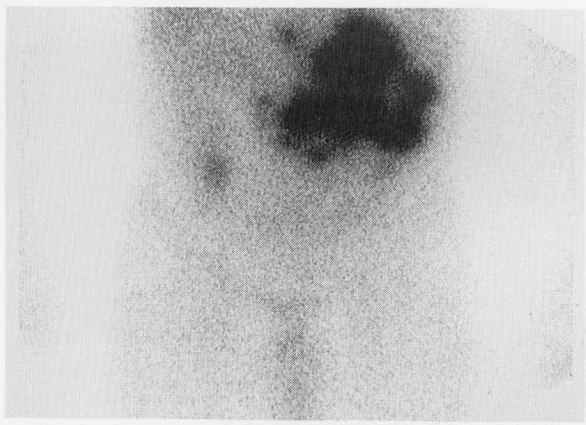

B

Fig. 2 Pretreatment gallium-67 scintigraphy, planar anterior and posterior images (A) and abdominal spot film (B) showing high uptake at the left mid abdominal area.

deteriorated until he finally expired due to respiratory arrest. Autopsy of the ileum coincided with posttherapeutic gallium findings and a definitive diagnosis of acute adult T-cell lymphoma was made (Figures 5A and B).

DISCUSSION

ATL is more frequent in males and incidence rates increase with age until the age of 70.[1] In the gastrointestinal tract, histiocytic lymphoma involves the stomach in 56%, small intestine in 25% and large intestine in 10% of patients. Abdominal pain is the most common presenting symptom followed by anorexia, weight loss, malaise and

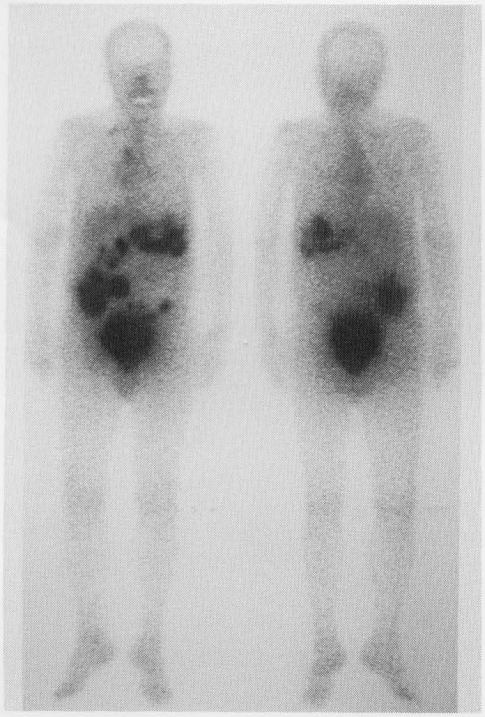

A

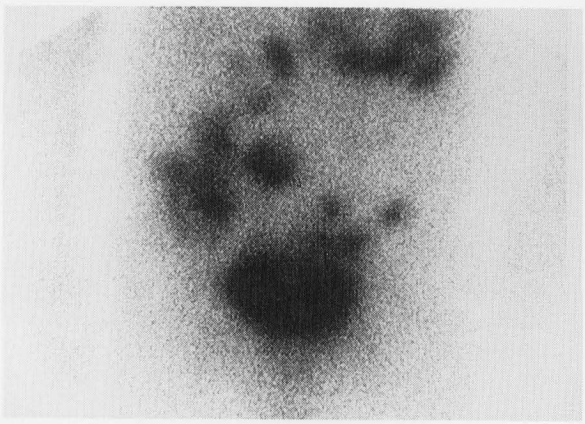

B

Fig. 3 Posttreatment gallium scintigraphy, planar anterior and posterior images (A) and abdominal spot film (B) showing no uptake in the areas included in the radiation field with accompanying increase in the uptake left hypochondrium, right lumbar and hypogastrium regions.

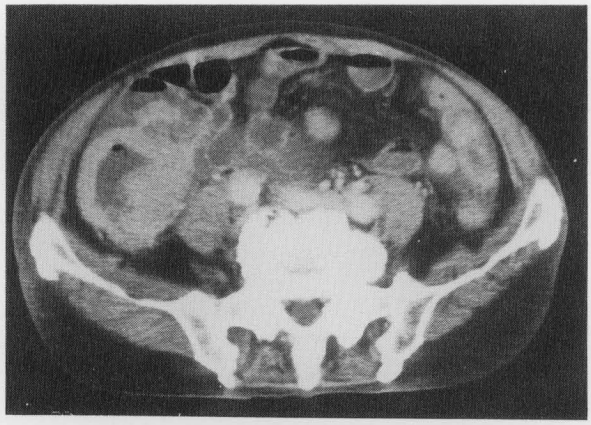

A

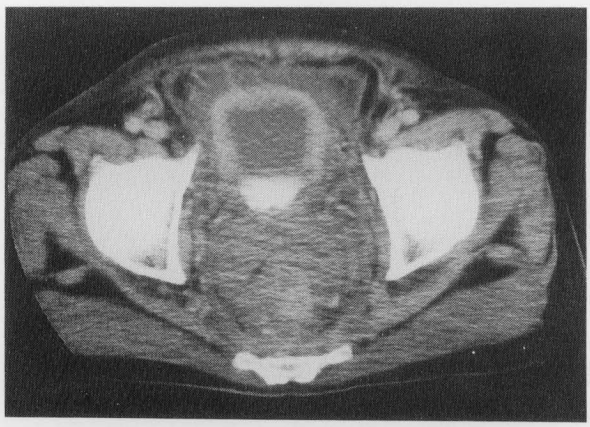

B

Fig. 4 Posttreatment computed tomography image of the lower abdomen demonstrating thickening of intestinal wall (A) and of lower pelvic level showing thickening of the wall of the bladder which is suggestive of progressive disease (B).

weakness. In 20% of patients an abdominal mass is detected.[5] Basing on abnormality in laboratory findings [lymphocytosis, hypercalcemia and high lactate dehydrogenase (LDH)], lymphadenopathy and involvement of other organs, Shimoya et al. classified ATL into smoldering, chronic, lymphoma and acute clinical subtypes.[6] The absence of a specific abnormality in peripheral blood examination and the involvement of only the abdomen as shown by Ga-67 lead to classification of our patient's condition as due to acute ATL. In localized diffuse histiocytic lymphoma as in our patient, radiotherapy is the treatment of choice.[7] Acute ATL has a median survival time of 6.2 months and has projected 2- and 4-year survival rates of only 16.7% and 5% respectively.[6] The poor prognosis in ATL could be attributed to its accompanying life threatening complication of infection and hypercalcemia.[8]

With lymphoma in general, Ga-67 is frequently used in disease staging, detecting relapse or residual, progressive disease at follow-up, predicting response to therapy and predicting outcome and prognosis.[3,9] With ATL, Ga-67 has a 68% positivity rate and was able to detect a malignant lesion initially in 38% of patients.[4] In low-grade non-Hodgkin's lymphoma it is used to monitor response to therapy and provide early detection of disease recurrence.[10] Positive Ga-67 was also associated with leukocytosis and high LDH which indicated a poor prognosis.[4]

In conclusion, Ga-67 has many uses in acute ATL. The distribution of uptake of Ga-67 in ATL could help in the clinical subtyping of patients. Localization of the lesion serves as a guide to the form of treatment. The extension

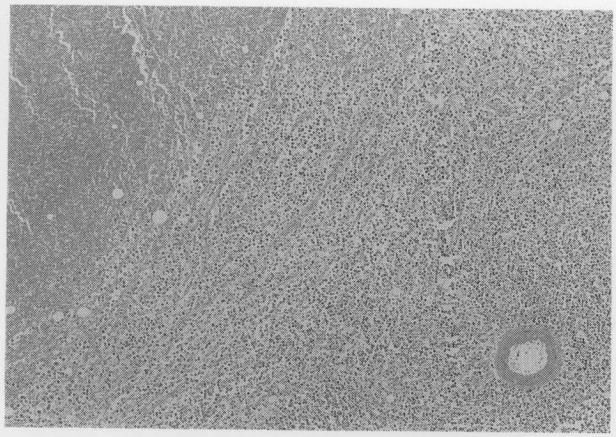

A

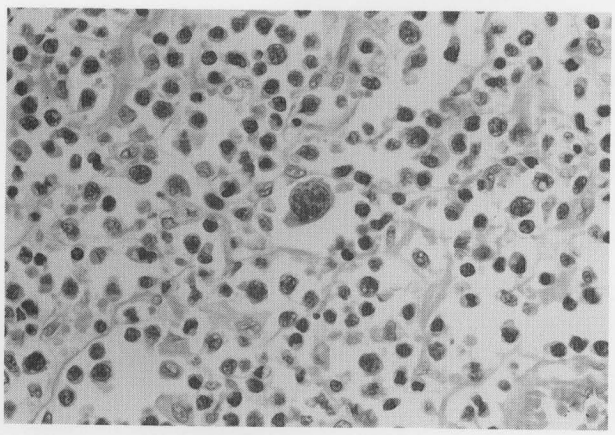

B

Fig. 5 Autopsy of the ileum showed diffuse proliferation of lymphoma cells with necrotic area at left upper corner due to radiation (A). The diffuse proliferation of lymphoma cells with polygonal hyperchromatic nuclei and giant cell is compatible with adult T-cell lymphoma (B).

of uptake after treatment is indicative of aggressiveness of the disease. Even the mere positivity of Ga-67 in ATL is suggestive of a poor prognosis.

REFERENCES

1. Tajima K. The 4th nation-wide study of adult T-cell leukemia/lymphoma (ATL) in Japan: estimates of risk of ATL and its geographical and clinical features. The T- and B-cell Malignancy Study Group. *Int J Cancer* 45: 237–243, 1990.
2. Shimoyama M. Peripheral T-cell lymphoma in Japan: recent progress. *Ann Oncol* 2: S157–162, 1991.
3. McLaughlin AF, Magee MA, Greenough R, Allman KC, Southee AE, Meikle SR, et al. Current role of gallium scanning in the management of lymphoma. *Eur J Nucl Med* 16: 755–771, 1990.
4. Hoshi H, Jinnouchi S, Harada K, Watanabe K. Gallium scintigraphy in patients with adult T-cell leukemia lymphoma. *Eur J Nucl Med* 14: 177–179, 1988.
5. Rosenfelt F, Rosenberg SA. Diffuse histiocytic lymphoma presenting with gastrointestinal tract lesions. The Stanford experience. *Cancer* 45: 2188–2193, 1980.
6. Shimoyama M. Diagnostic criteria and classification of clinical subtypes of adult T-cell leukaemia-lymphoma. A report from the Lymphoma Study Group (1984–87). *Br J Haematol* 79: 428–437, 1991.
7. Levitt SH, Bloomfield CD, Frizzera G, Lee CK. Curative radiotherapy for localized diffuse histiocytic lymphoma. *Cancer Treat Rep* 64: 175–177, 1980.
8. Tamura K. Clinical classification of adult T-cell leukemia and its complications. *Rinsho Byori* 44: 19–23, 1996.
9. Front D, Israel O. The role of Ga-67 scintigraphy in evaluating the results of therapy of lymphoma patients. *Semin Nucl Med* 25: 60–71, 1995.
10. Ben-Haim S, Bar-Shalom R, Israel O, Haim N, Epelbaum R, Ben-Shachar M, et al. Utility of gallium-67 scintigraphy in low-grade non-Hodgkin's lymphoma. *J Clin Oncol* 14: 1936–1942, 1996.